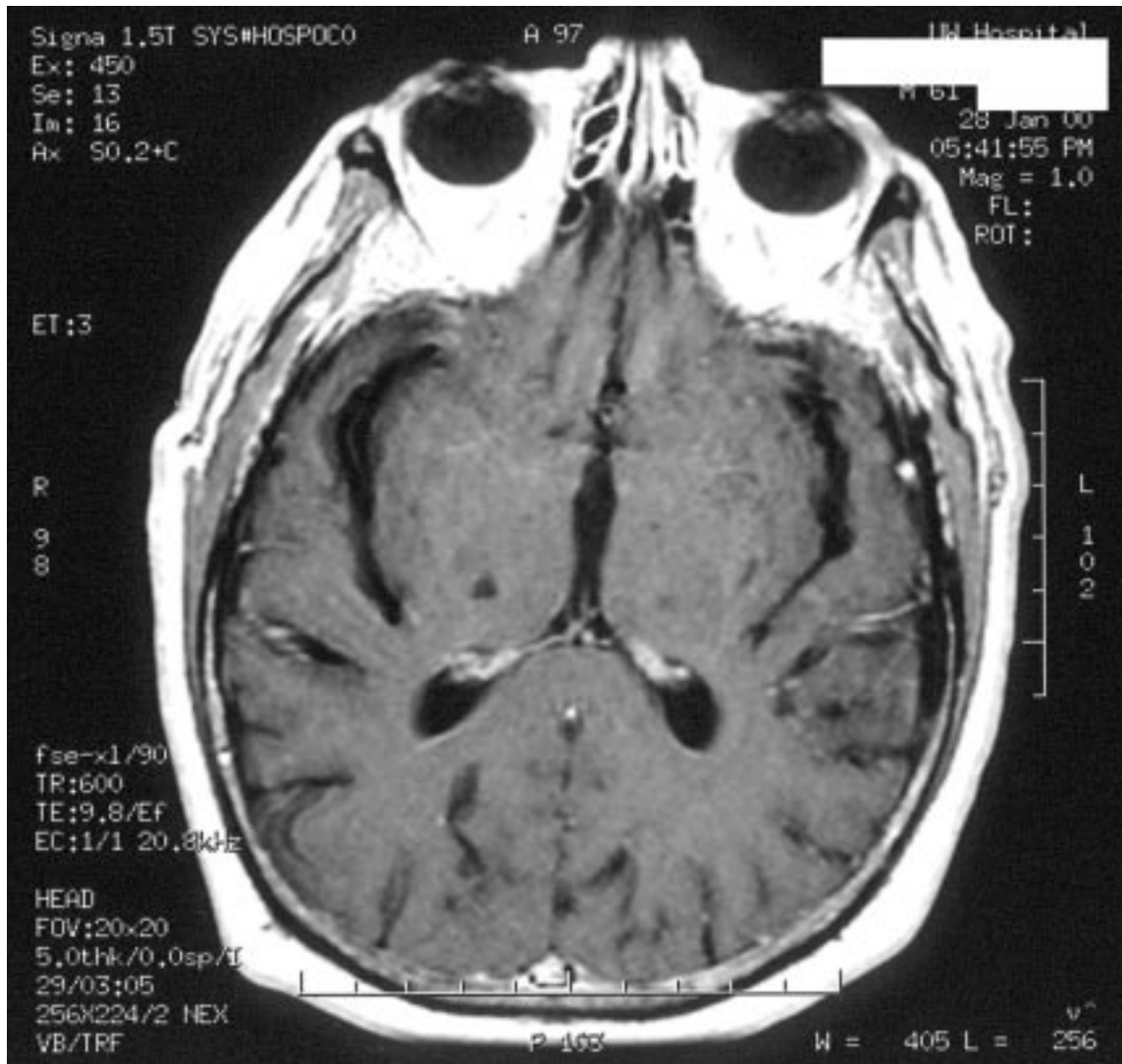


## THALAMUS

Here is a case history that you should be able to answer at the end of this lecture.

A 45 y.o. woman presents to the emergency room with a headache and complains of abnormal sensations on the left side of her body. She claims that the sensory changes came on rapidly in the last few hours. Her lab reports come back normal, a spinal tap reveals normal CSF, and her mental ability seems good. You perform a neurological exam and find she has greatly reduced sensation on the entire left side of her body, including her face. The sensory loss includes all modalities. The motor exam is normal, as is her visual exam and hearing exam. An MRI is performed and the results are seen below.



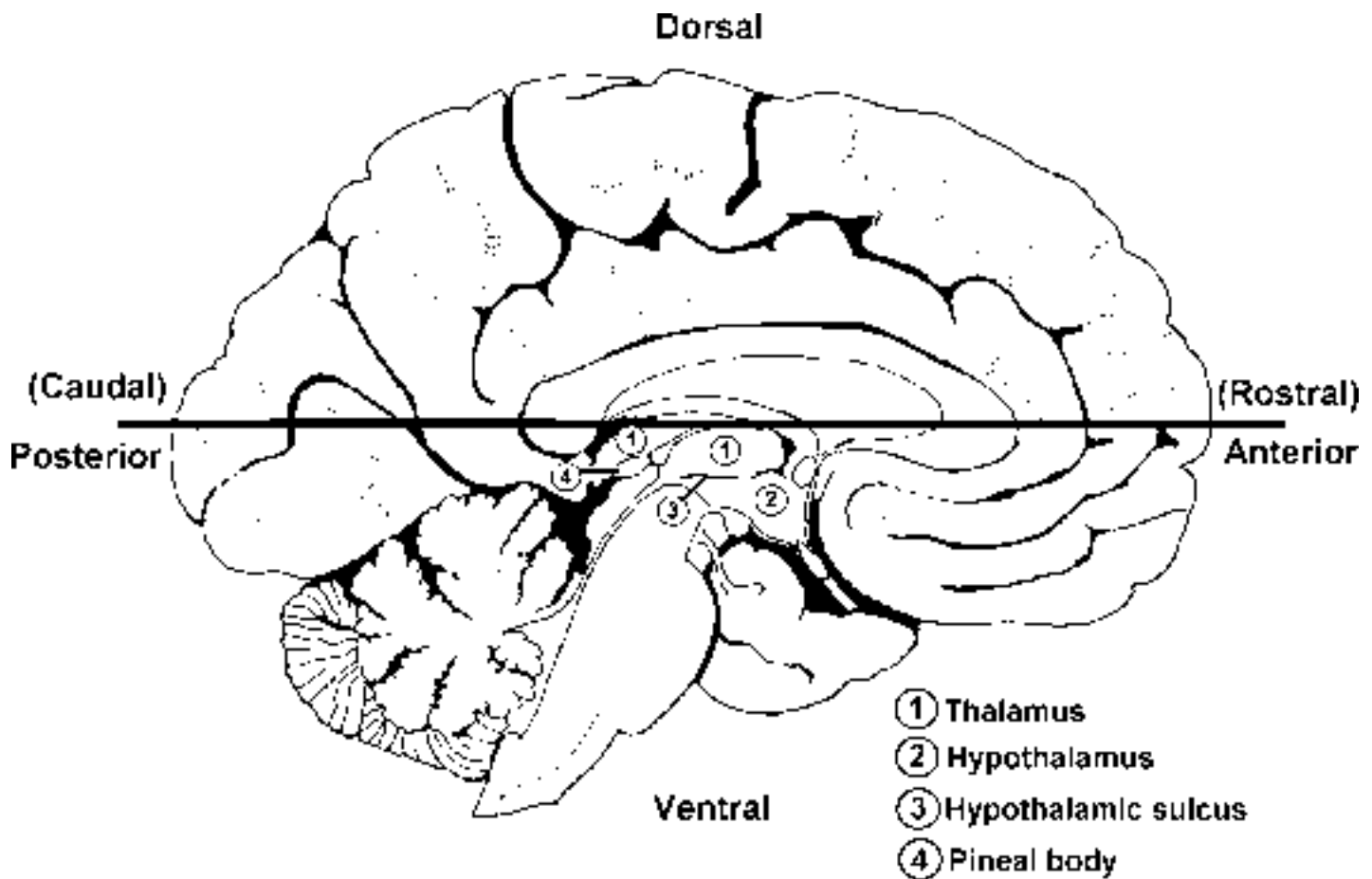
Based on her neurological findings, which thalamic nuclei should be involved in this small lesion? Does your prediction correlate with the position of the lesion on the MRI?

Without looking at the MRI, how could you tell this was a thalamic lesion and not a problem with sensory cortex?

Which artery was probably involved in this lesion?

How do you know the lesion didn't include the geniculate bodies?

This lecture will focus on the thalamus, a subdivision of the diencephalon. The diencephalon can be divided into four areas, which are interposed between the brain stem and cerebral hemispheres. The four subdivisions include the hypothalamus to be discussed in a separate lecture, the ventral thalamus containing the subthalamic nucleus already discussed, the epithalamus which is made up mostly of the pineal body, and the dorsal thalamus (henceforth referred to as the thalamus) which is the focus of this lecture. Although we will not spend any time in lecture on the pineal body, part of the epithalamus, it does have some interesting features as well as some clinical relevance. The pineal is a small midline mass of glandular tissue that secretes the hormone melatonin. In lower mammals, melatonin plays a central role in control of diurnal rhythms (cycles in body states and hormone levels that follow the day-night cycle). In humans, at least a portion of the control of diurnal rhythms has been taken over by the hypothalamus, but there is increasing evidence that the pineal and melatonin play at least a limited role. Recent investigations have demonstrated a role for melatonin in sleep, tumor reduction and aging. Additionally, based on the observation that tumors of the pineal can induce a precocious puberty in males it has been suggested that the pineal is also involved in timing the onset of puberty. In many individuals the pineal is partially calcified and can serve as a marker for the midline of the brain on x-rays. Pathological processes can sometimes be detected by a shift in its position. Fig 1 above is a medial view of the left hemisphere showing the relationship between the dorsal thalamus,



hypothalamus and the pineal body of the epithalamus. Notice there is a rather deep groove, the hypothalamic sulcus (number 3) that separates the thalamus from the hypothalamus. The bold line running from anterior (rostral) to posterior (caudal) indicates the approximate level of a horizontal section shown in figure 2 below.

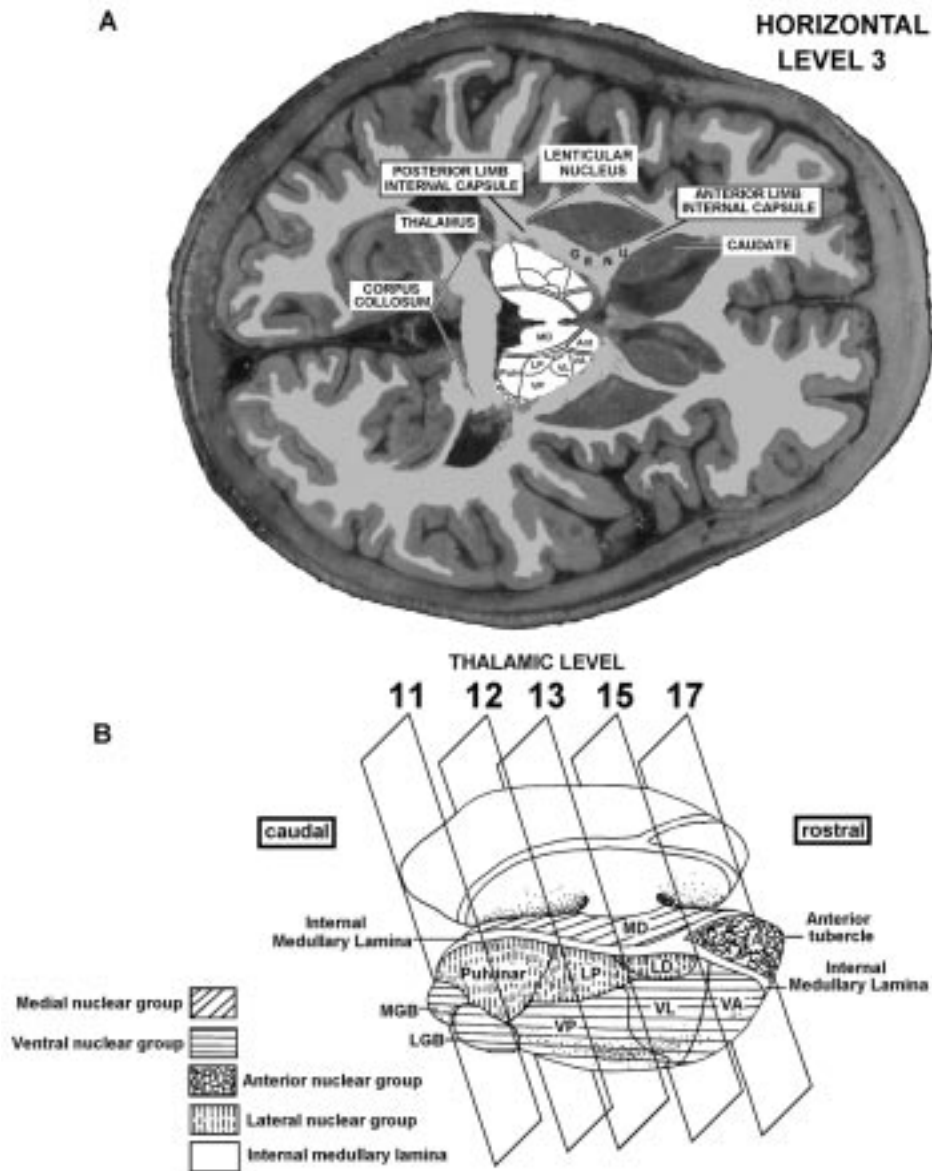


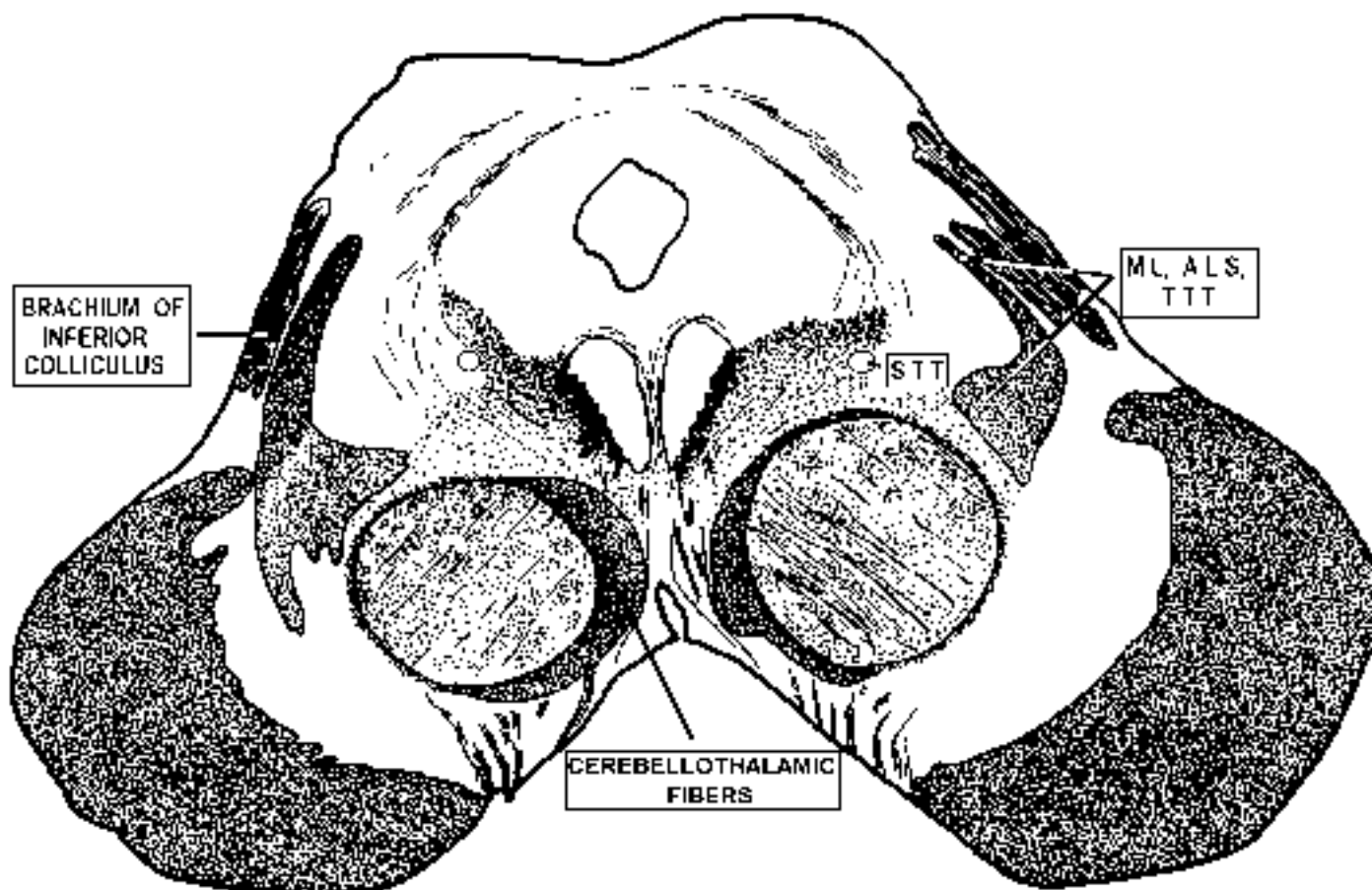
Fig. 2A horizontal section of both hemispheres with the thalamus highlighted to show the major subdivisions. 2B. Thalamus extracted and enlarged to show major subdivisions and points of section for levels 11-17.

In figures 2A and B the thalamus has been highlighted and the most prominent divisions of the thalamus have been indicated for orientation purposes. The highlighted thalamus has then been extracted and blown up in figure 2B to show the view that will be the standard diagrammatic representation for the remainder of this handout. Also seen in figure 2B are the approximate rostral to caudal positions of the standard frontal sections that you should be learning. Notice that levels 11-17 all contain at least a portion of the thalamus and are therefore relevant for this discussion. Figure 2B also shows the method, which we will use, to subdivide the thalamus. While there are several schemes for such subdivision, the most common one makes use of the internal medullary lamina to divide it on topographical grounds. The internal medullary lamina can be seen in most of the frontal sections (see figures 9-11). There is another lamina, the external medullary lamina, which separates the thalamus from the ventral thalamus and is of no importance for our discussion.

The internal medullary lamina is a thin sheet of white matter that runs longitudinally through the thalamus, separating it into medial and lateral nuclear masses. The medial mass consists of the medial nuclear group; the lateral mass contains the lateral nuclear group and the ventral nuclear group. In the rostral part of the thalamus the internal medullary lamina splits to form a partial capsule around the anterior nuclear group. Finally, a fifth nuclear group, termed the intralaminar nuclear group, is found within the confines of the internal medullary lamina and is therefore not seen in this diagrammatic representation. The different nuclear groups are indicated by capitol letters and by different shading patterns in Fig. 2B. In the remainder of the handout each of the nuclear groups will be briefly discussed.

In the spinal cord and brain stem portions of the course you learned about certain “relay” nuclei of the thalamus that transfer information from sub-cortical structures to the cerebral cortex. By virtue of these relay functions that encompass the major senses and motor systems, the thalamus is often referred to as the gateway to the cortex. You should bear in mind, however, that the thalamus does far more than relay sensory and motor information. In the first place, it does not simply relay information, but integrates it and regulates its transfer in complex ways. Secondly, the thalamus is involved in many functions that cannot be considered as sensory or motor. Although we have not emphasized it yet, you should know that **the projection from the thalamus to the cortex uses the internal capsule, both the anterior and posterior limbs.** ). This portion of the internal capsule is known as the thalamic radiation. In order to help you learn the thalamus I will start with the thalamic nuclei relevant to the major sensory and motor systems, which you already know (see figure 3). For each of these nuclei, we will consider the inputs, outputs and position in the thalamus starting from the posterior of the thalamus (the section above your last brain stem level. Notice that all six of these nuclei are found in the ventral nuclear group of the lateral mass. We will then come back to the thalamic nuclei that are new to you.

## ASCENDING PATHWAYS HEADED TO THALAMUS



- BRACHIUM OF THE INFERIOR COLLICULUS** - Cells of origin = ipsi inferior colliculus  
 termination = medial geniculate body
- MEDIAL LEMNISCUS** - Cells of origin = contra nucleus gracilis and cuneatus  
 termination = VPL
- ANTEROLATERAL SYSTEM** - Cells of origin = contra dorsal horn  
 termination = VPL
- TRIGEMINOTHALAMIC TRACT** - Cells of origin = contra spinal nucleus V (for pain and temp.)  
 termination = VPM
- SOLITARIOTHALAMIC TRACT** - Cells of origin = ipsi nucleus solitarius  
 termination = VPM
- CEREBELLOTHALAMIC FIBERS** - Cells of origin = contra deep cerebellar nuclei (esp. dentate nucleus)  
 termination = VA, VL

Fig. 3 Rostral midbrain section demonstrating the six ascending fiber bundles which you have previously studied that are heading for thalamus. Each ascending fiber system is paired with its cell of origin and the thalamic nucleus of termination.

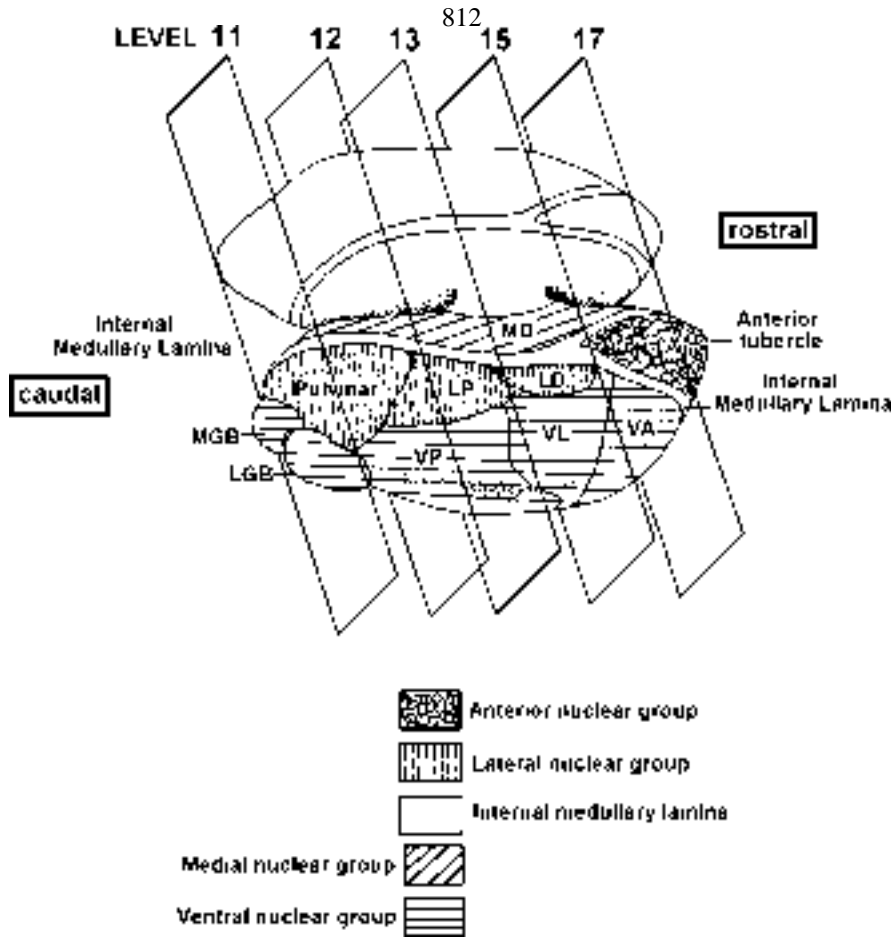
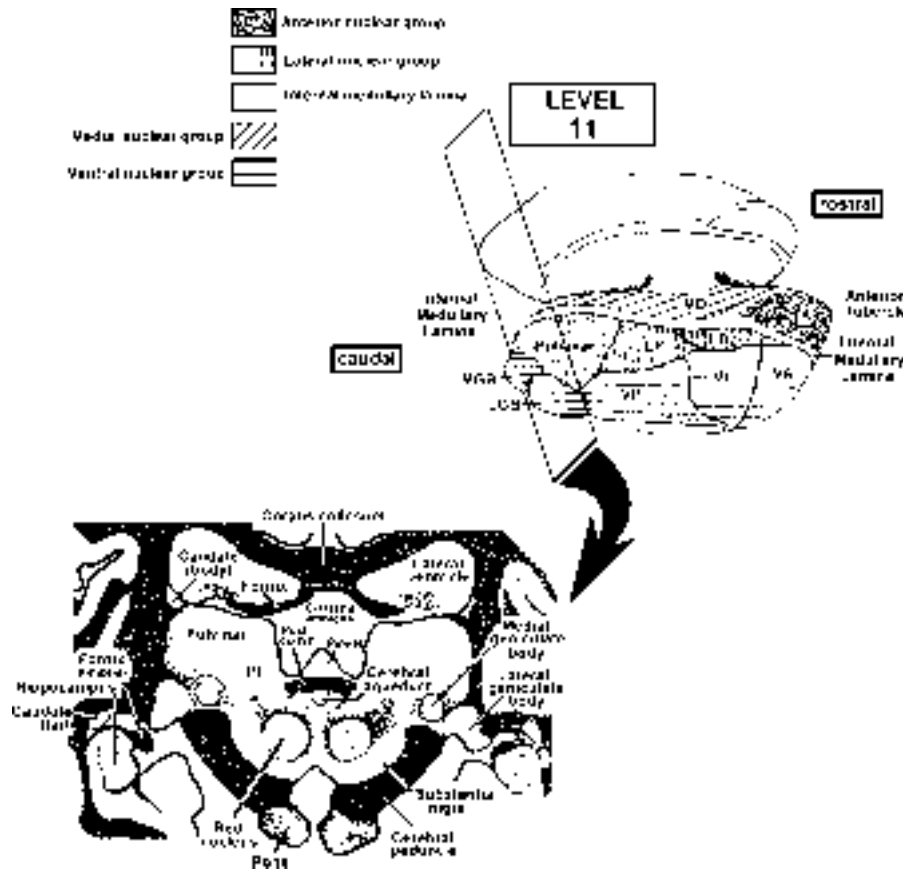
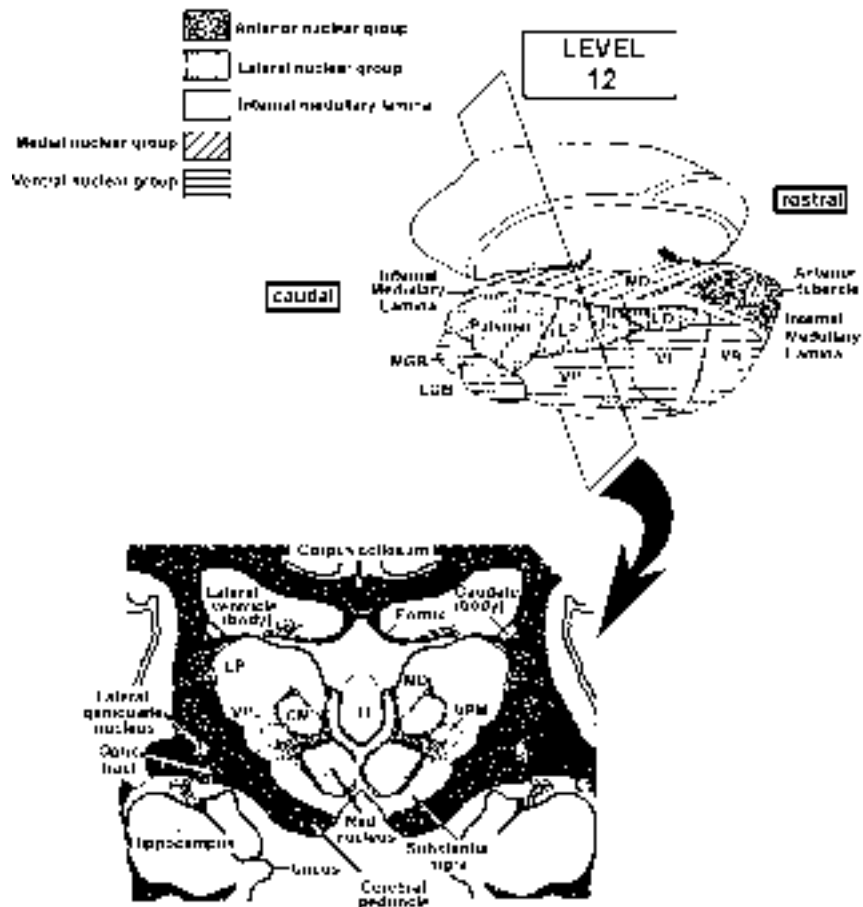


Fig. 4 Drawing of an isolated thalamus showing the plane of section (frontal) and the relative location of the levels through the thalamus (levels 14 and 16 not shown). Shadings indicate various nuclear groups.

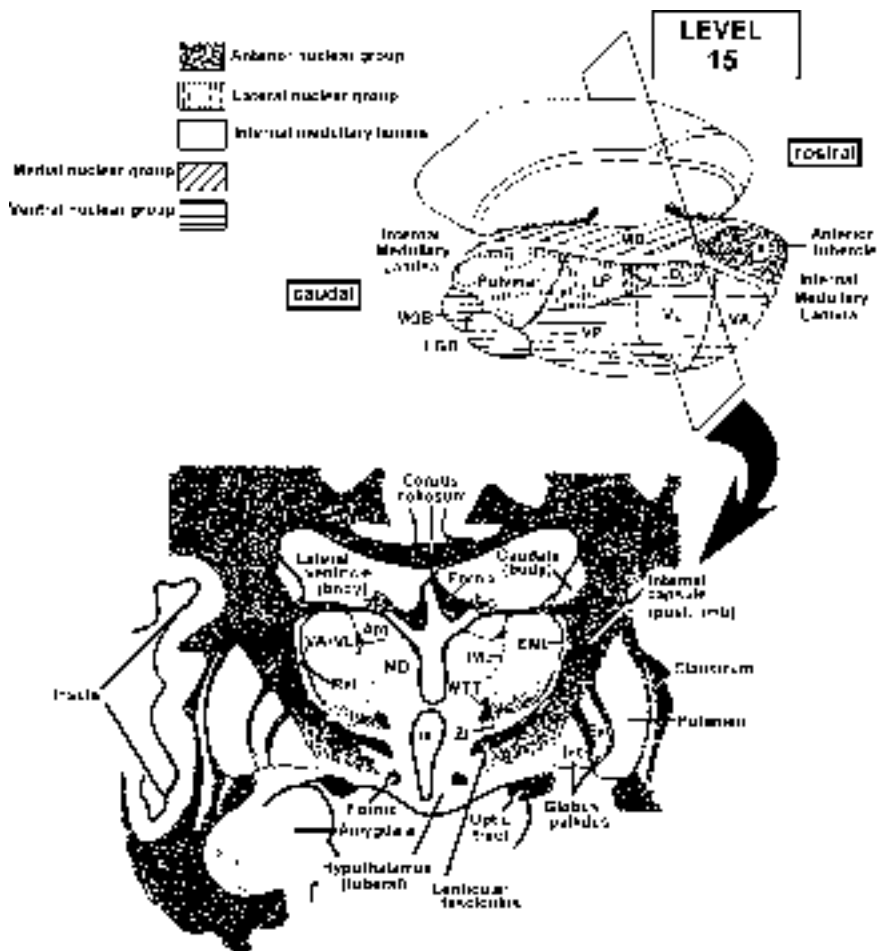


The following three figures show the location of the six thalamic nuclei of the ventral group beginning from the posterior border of the thalamus.

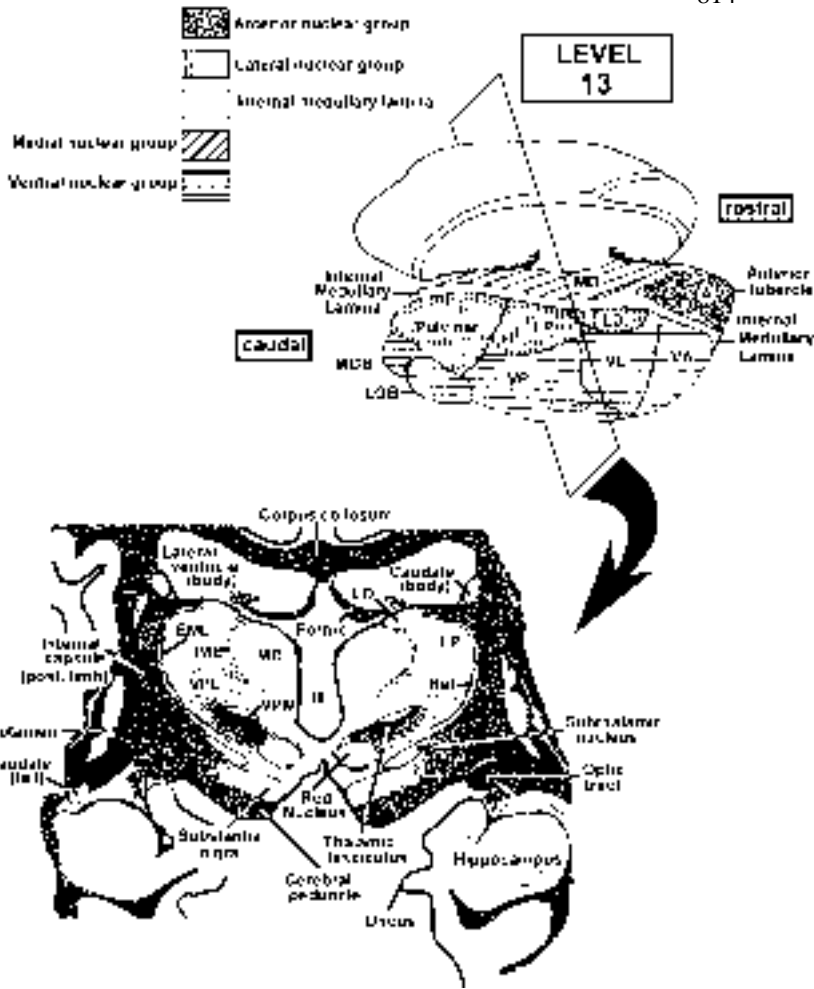
Level 11 at left demonstrates the medial and lateral geniculate bodies. To review, these two thalamic nuclei are the visual (LGB) and auditory (MGB) relay nuclei, and project to the primary visual (area 17) and primary auditory (area 41,42) cortical areas.



Ventral group nuclei seen in level 12 include the VPM and VPL. These two nuclei should be very familiar to you. Recall that they receive inputs from the DC-ML, LSTT to the VPL, and the TTT and STT to VPM. They in turn project to the Primary sensory cortex, area 3,1,2.

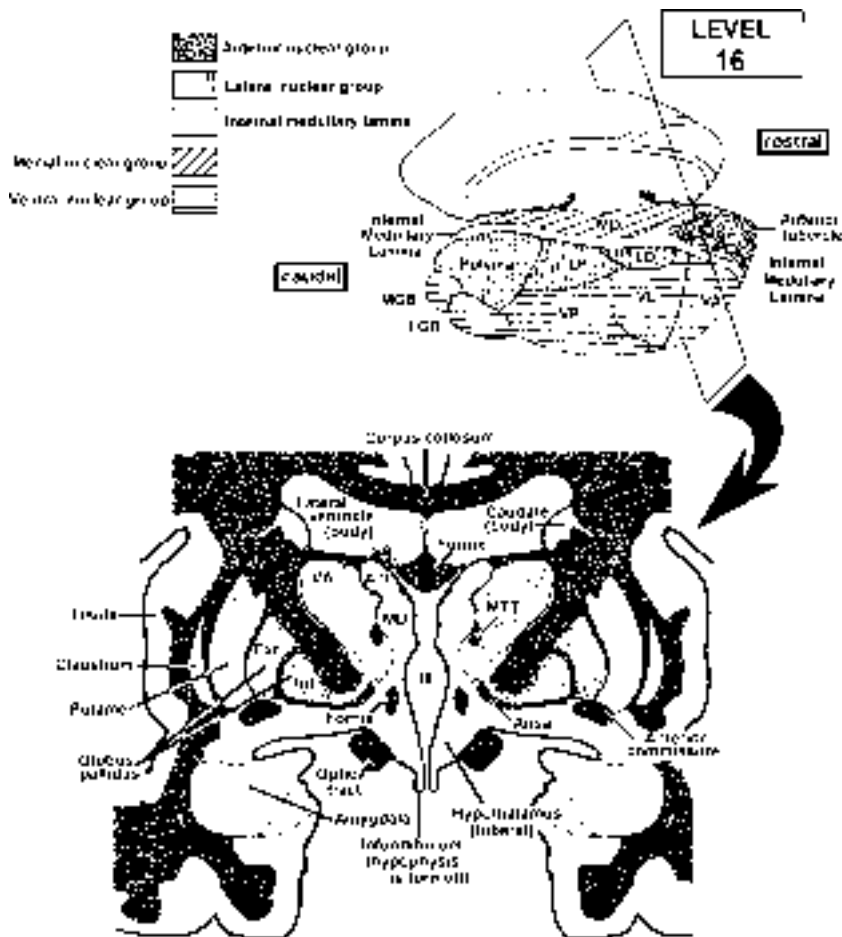


Ventral group nuclei seen in level 15 include the VA and VL nuclei. It is difficult to tell the difference between VA and VL so we are going to group them together. Recall that these two nuclei are the motor relay nuclei, receiving inputs from the cerebellum and the basal ganglia. Do you remember the names of the pathways that project to these nuclei? There are two landmarks that indicate that you are nearing the anterior pole of the thalamus which will help you identify the VA/VL complex. They are the MTT and the IML as it wraps around the anterior nucleus.



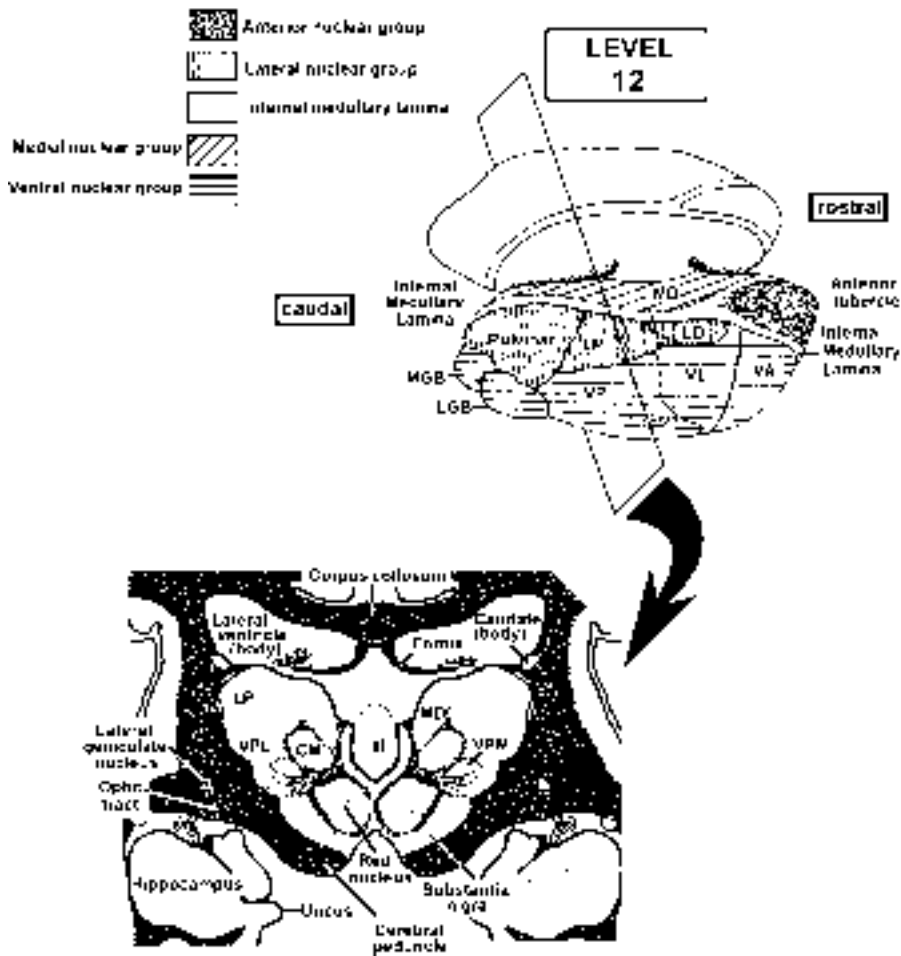
Now that we have looked at the six thalamic nuclei associated with primary cortical areas, let's take a look at the remaining thalamic nuclei.

One of the easiest nuclei to identify is the Medial Dorsal (MD) because it is present through most of the rostral-caudal extent of the thalamus. It is most obvious in level 13, but you should recognize it at many levels. The medial dorsal nucleus is the only nucleus in the medial group, and it receives two kinds of inputs. Part of this nucleus receives pain afferents from the LSTT and the TTT, projects to the frontal lobe, and is involved in the response to pain. The other part of MD receives olfactory inputs from primary olfactory cortex. This nucleus is unique because it receives these olfactory inputs after they have been to cortex, and then relays them to insular and orbitofrontal cortex for associative olfactory functions.

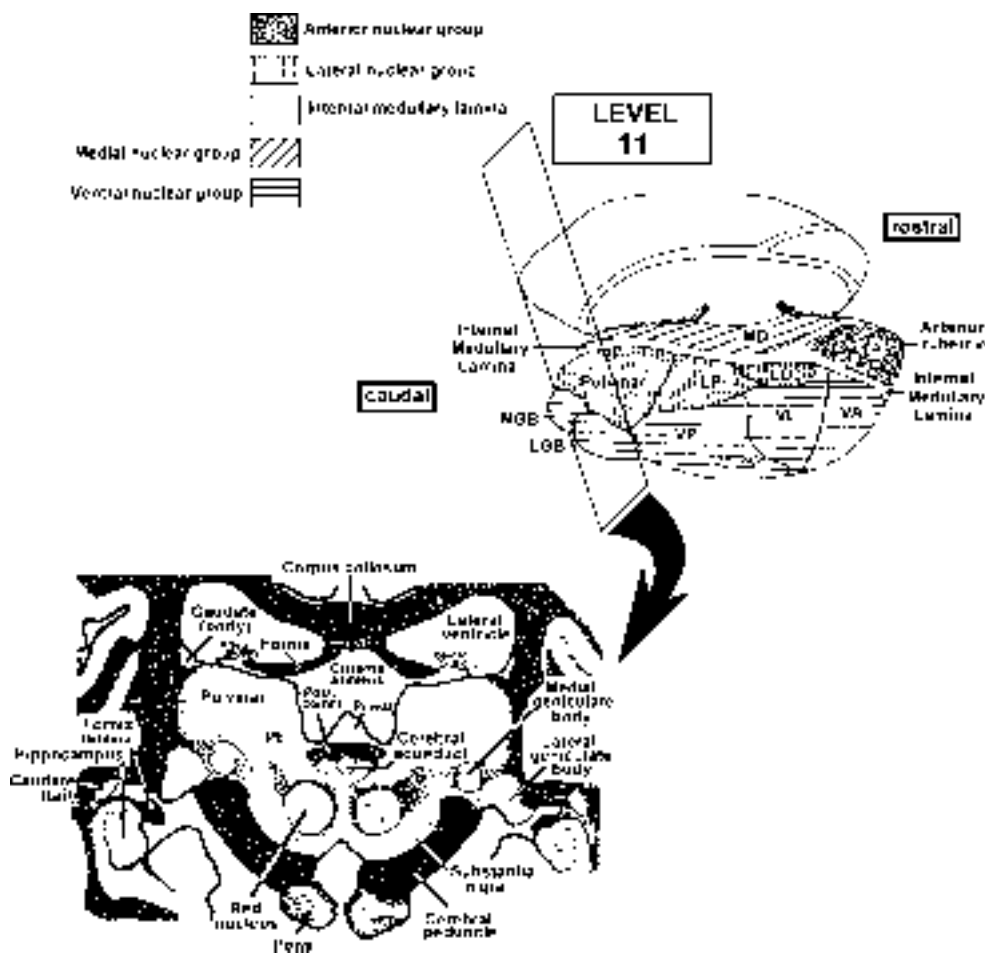


The Anterior nuclear group (Ant) is another easy nucleus to identify because of its association with the internal medullary lamina (IML). We will always ask you to identify this nucleus with the IML and MTT present. This nucleus is involved in the relay of visceral and emotional information to limbic system structures. It receives inputs from the MTT and limbic system and projects to the cingulate gyrus. I think it is helpful to think of the cingulate gyrus as the motor cortex of the limbic system (sort of visceral motor cortex).





The last nucleus, which is relatively easy to identify, is the centro-median nucleus (CM). This is the only nucleus of the intralaminar group that you need to identify. We know very little about this nucleus due to its deep location, but we do know that it has some major connections to the motor systems basal ganglia. Other nuclei of this group receive pain afferents and play a role in pain perception. The intralaminar nuclei are also involved in control of the sleep-waking cycle (see EEG and Sleep in module 3 lecture notes).



Finally, we are left with the lateral group nuclei of which there is only one that I want you to know. The pulvinar is the only nucleus of this group to identify. This nucleus receives inputs from many diverse areas of the major sensory systems and projects to the all of the association areas of cortex in the parietal, occipital and temporal lobes. One of the primary outputs of pulvinar is to the secondary visual areas (18 and 19). There is evidence that this secondary pathway conveys information only about stimulus position and is not involved in pattern recognition. For our purposes you should think of the pulvinar as an area, which can direct your attention to a new stimulus like a flash of light or a sound.

You probably noticed that we left out the Lateral Dorsal (LD) and the Lateral Posterior (LP) nuclei from our discussion. We will not hold you responsible for these two nuclei as we know very little about them.

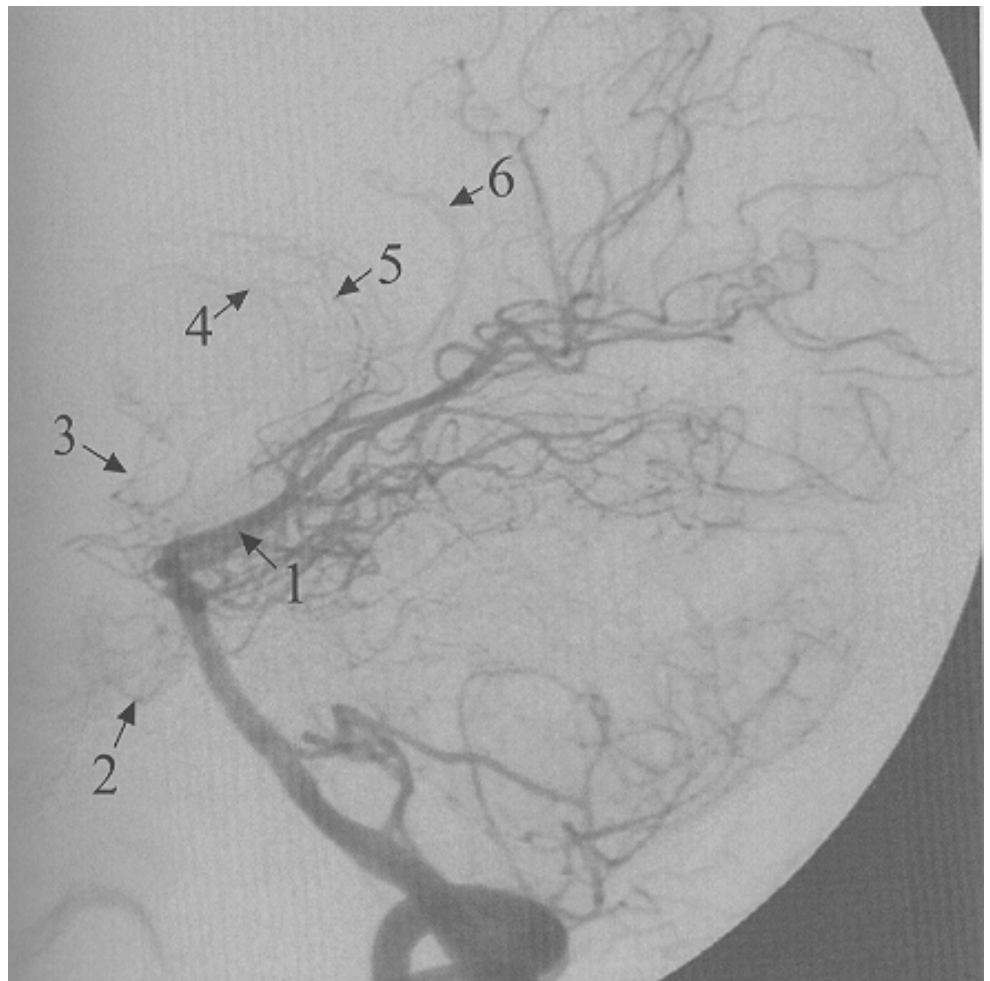Although I did not discuss the reticular nuclei you should at least be familiar with the name. This group of nuclei is involved in the regulation of sleep wake cycles, and has diffuse projections to all other thalamic nuclei, but is the only thalamic nucleus that does not project to the cortex.

### Symptoms Following Lesions of the Thalamus

There are two considerations that must be taken into account when attempting to diagnose lesions of the thalamus: 1) thalamic nuclei are small so that lesions producing highly specific effects are uncommon (although they do occur), and 2) the thalamus is immediately bounded by the internal capsule and is in close proximity to the deep motor nuclei of the cerebral hemisphere (putamen, caudate and globus pallidus) so that thalamic lesions frequently are accompanied by symptoms from damage to these other structures (most commonly from hemorrhage from the striate arteries—discussed in cortex lectures).

However, since small branches of the posterior cerebral artery supply much of the thalamus but not adjacent structures, selective thalamic lesions do occur. Occlusion of these small branches results in a number of symptoms characteristic of the thalamic syndrome.

The angiogram at the right is a lateral view of the vertebral basilar system showing the posterior cerebral vessel and its branches. The small branches (3) are thalamoperforating. Can you see the outlines of the cerebellum (what three arteries supply the cerebellum)? Damage to the thalamoperforating branches can cause a thalamic syndrome (see below).



- 1) If the damage includes VPL and VPM a contralateral hemianesthesia usually results. Typically, all somatic sensory modalities are affected: light touch, conscious proprioception, 2-point discrimination & vibration, and pain & temperature. *This loss of all somatic sensory modalities is an important diagnostic sign for thalamic damage (lesions of the internal capsule or cortex that impair somatic sensory function typically affect different modalities to different extents, often leaving pain sensation unchanged).*
  
- 2.) Sometimes seen after a period of recovery from damage to VPL and VPM (days to months) is hyperalgesia (an exaggerated unpleasant or painful sensation resulting from mild cutaneous stimulation) or in some cases spontaneous pain with no apparent stimulation (**causalgia**). Such pain can be severe and intractable. Hyperalgesia and spontaneous pain do not occur with lesions confined to the cerebral hemispheres (cortex, internal capsule, or deep nuclei). Obviously, damage to the postero-lateral part of the thalamus also will involve other nuclei such as the pulvinar and lateral posterior, but unilateral infarcts in these higher order “association” nuclei typically result in no obvious deficits.
  
- 3.) If the LGB is affected there is a **contralateral homonymous hemianopsia**.
  
- 4) If the damage extends into the VA/VL nuclei complex movement disorders can result. *The movement disorders can be reminiscent of cerebellar damage (ataxia and intention tremor) and/or basal ganglia damage (choreoathetoid movements).* This reflects, in part, the fact that both the cerebellum and basal ganglia project to VA and VL. All such problems occur contralateral to the side of the lesion.



| GROUP                  | NUCLEI   | RECEIVES INPUT FROM   | CORTICAL CONNECTIONS  |
|------------------------|--|---|---|
| Anterior Nuclear Group | no important named nuclei  | Limbic system (including mammillary bodies)   | Cingulate Gyrus   |
| Medial Nuclear Group   | Mediodorsal (only large nucleus of the medial group)   | Olfactory cortex and spinothalamic (ALS; pain) afferents  | Pain is relayed to prefrontal cortex. Olfactory information is relayed to insular and orbitofrontal cortex  |
| Lateral Nuclear Group  | Lateral dorsal (unimportant)<br><br>Pulvinar and Lateral posterior (unimportant)   | Limbic system<br><br>many different sources   | Cingulate gyrus<br><br>Parietal, temporal, occipital "association cortex"   |
| Ventral Nuclear Group  | Ventral lateral and Ventral anterior<br><br>Ventral posterior nucleus:<br>Posterolateral division<br>Posteromedial division<br><br>Medial geniculate body<br><br>Lateral geniculate body | Cerebellum<br>Globus pallidus<br>Substantia Nigra (pars reticulata)<br><br>Medial lemniscus, ALS<br>TTT, STT<br><br>Inferior colliculus<br><br>Retinal ganglion cells | Motor, pre-motor and supplementary motor cortex (Areas 4 and 5)<br><br>Somatic sensory cortex (Areas 3,1 and 2) and to a lesser extent motor cortex (Area 4)<br>Taste to Insular cortex<br><br>Auditory cortex (Areas 41 and 42)<br><br>Primary visual cortex (striate cortex: Area 17) |
| Intralaminar Group     | Sheet-like<br><br>Centromedian (largest intralaminar nucleus)  | Ascending input from the spinal cord (spinothalamic fibers), reticular formation and other areas<br><br>Globus pallidus and Substantia nigra (pars reticulata)        | Diffuse<br><br>Motor cortex (also projects to striatum)   |

## SUMMARY OF IMPORTANT POINTS FROM THALAMUS LECTURES

Points you should concentrate on are as follows:

1) Spatial relationships between the diencephalon and the different components of the cerebral hemispheres (internal capsule, caudate, putamen, globus pallidus, ventricles, etc.). This is, of course, essential for interpretation of C-T scans, and diagnosing problems resulting from lesions involving more than one of these areas.

2) Organization of the dorsal thalamus. It is important for you to retain a sense of the 3-D relationships between different thalamic nuclei and I have, therefore, stressed the subdivisions of the thalamus into nuclear groups and positions of these groups with respect to the internal and external medullary laminae and other landmarks. Since nuclei within the different subdivisions of the diencephalon and nuclear groups of the dorsal thalamus tend to have similar connections and/or functions, knowing these groups will also help you to remember details concerning individual nuclei. Don't confuse the ventral nuclear group of the dorsal thalamus with the ventral thalamus.

3) Another useful starting point in learning the details of connections and functions of individual nuclei in the dorsal thalamus is to categorize them according to functional types: VA and VL are motor "relay" nuclei; VP (VPL & VPM), MGB, LGB and MD are sensory "relay" nuclei (don't forget the taste relay in the medial part of VPM); LP, Pulvinar and MD are connected with association areas of cortex; the anterior nuclear group nuclei and LD have connections with limbic structures; the thin sheet-like nuclei in the intralaminar group receive nociceptive spinothalamic fibers (so do VPL and MD) and are part of the reticular activating system; the CM nucleus of the intralaminar group has connections with motor areas of the brain.

4) Thalamic syndromes. It is important to know the different types of deficits resulting from damage to the thalamus and to remember that the thalamus can be selectively damaged with little or no damage to the internal capsule or deep motor nuclei by blockage of the thalamoperforating branches of the posterior cerebral artery.

After you learn about the effects of lesions of the internal capsule and cerebral cortex in later lectures, think about how you would distinguish deficits resulting from thalamic lesions from those resulting from damage to these other areas.

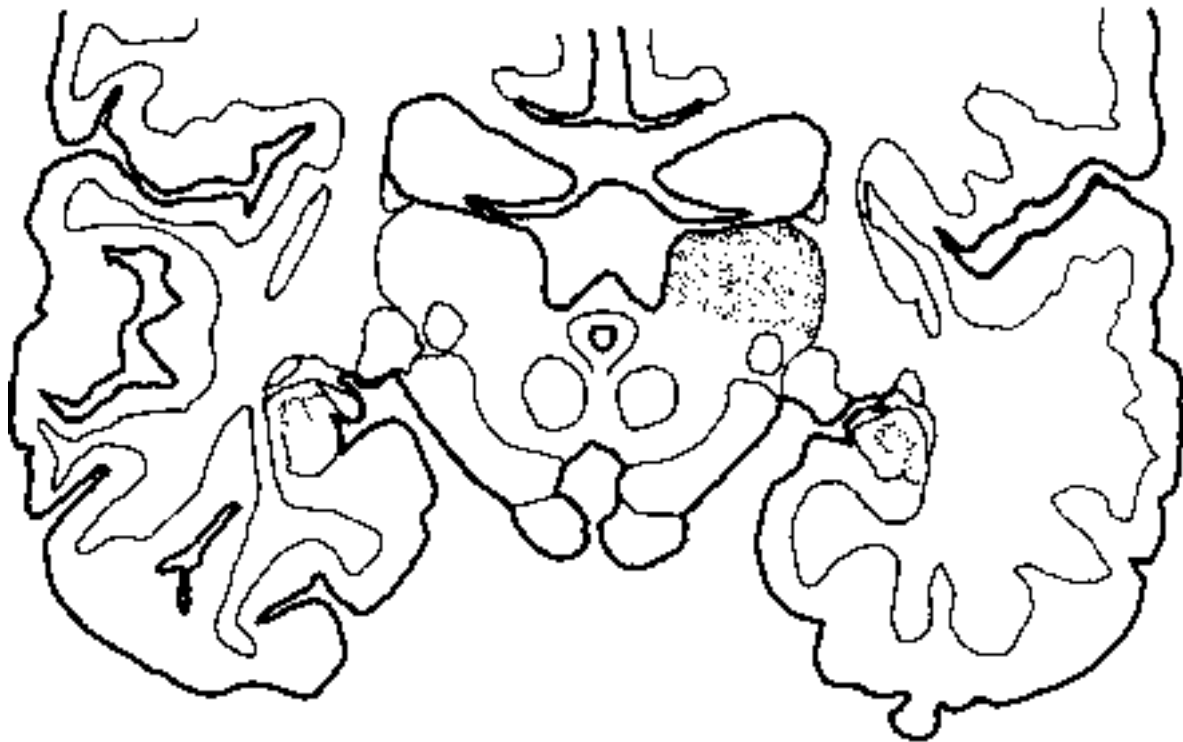
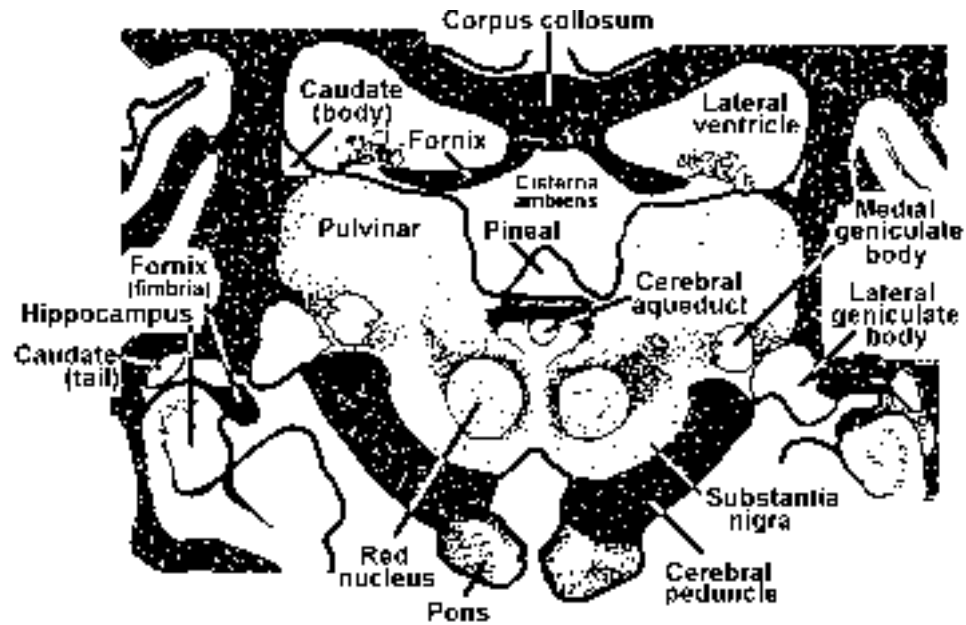
**PRACTICE QUESTIONS - THALAMUS****multiple choice** (one correct answer):

1. The diencephalon is divided into symmetrical halves by the:
  - A. fourth ventricle
  - B. hypothalamic sulcus
  - C. stria medullaris
  - D. third ventricle
  - E. lateral ventricle
  
2. The lateral surface of the diencephalon is bounded by the:
  - A. third ventricle
  - B. lateral ventricle
  - C. internal capsule
  - D. internal medullary lamina
  
3. Which of the following statements is **FALSE** concerning thalamic syndrome:
  - A. the pain involved may be very disagreeable and may become intractable to analgesics.
  - B. the syndrome usually results from a lesion that is vascular in origin.
  - C. the symptoms of the syndrome vary according to the location and extent of the lesion.
  - D. the threshold for somatic sensory stimuli is usually raised on the same side of the body as the lesion.
  - E. blockage of the posterior cerebral or its thalamic branches can cause the thalamic syndrome.
  
4. The largest nucleus within the intralaminar group is:
  - A. centromedian
  - B. pulvinar
  - C. lateral dorsal
  - D. mediodorsal
  - E. ventral anterior
  
5. The mediodorsal (dorsomedial) nucleus projects to the \_\_\_\_\_ lobe.
  - A. frontal
  - B. parietal
  - C. occipital
  - D. temporal
  - E. ear
  
6. Which of the following nuclei is (are) recognized in the ventral nuclear group of the thalamus?
  - A. ventral posterior
  - B. ventral lateral
  - C. ventral anterior
  - D. lateral geniculate
  - E. all of the above

7. Which of the following nuclei relay(s) somatosensory information?
- A. ventral posterior lateral
  - B. medial geniculate
  - C. reticular
  - D. ventral anterior
  - E. lateral geniculate
8. Which of the following thalamic nuclei is(are) thought to have a predominantly motor function?
- A. ventral posterior lateral
  - B. mediodorsal
  - C. ventral lateral
  - D. lateral posterior
  - E. pulvinar
9. The lateral nuclear group of the thalamus includes the:
- A. pulvinar
  - B. centromedian
  - C. anterior
  - D. mediodorsal
  - E. ventral lateral
10. Which of the following nuclei of the thalamus are sensory relay nuclei?
- A. ventral posterior medial
  - B. medial geniculate
  - C. lateral geniculate
  - D. ventral posterior lateral
  - E. all of the above
11. Which of the following nuclei receive nociceptive anterolateral input?
- A. mediodorsal
  - B. sheet-like nuclei in intralaminar group
  - C. VPL
  - D. pulvinar
  - E. two of the above

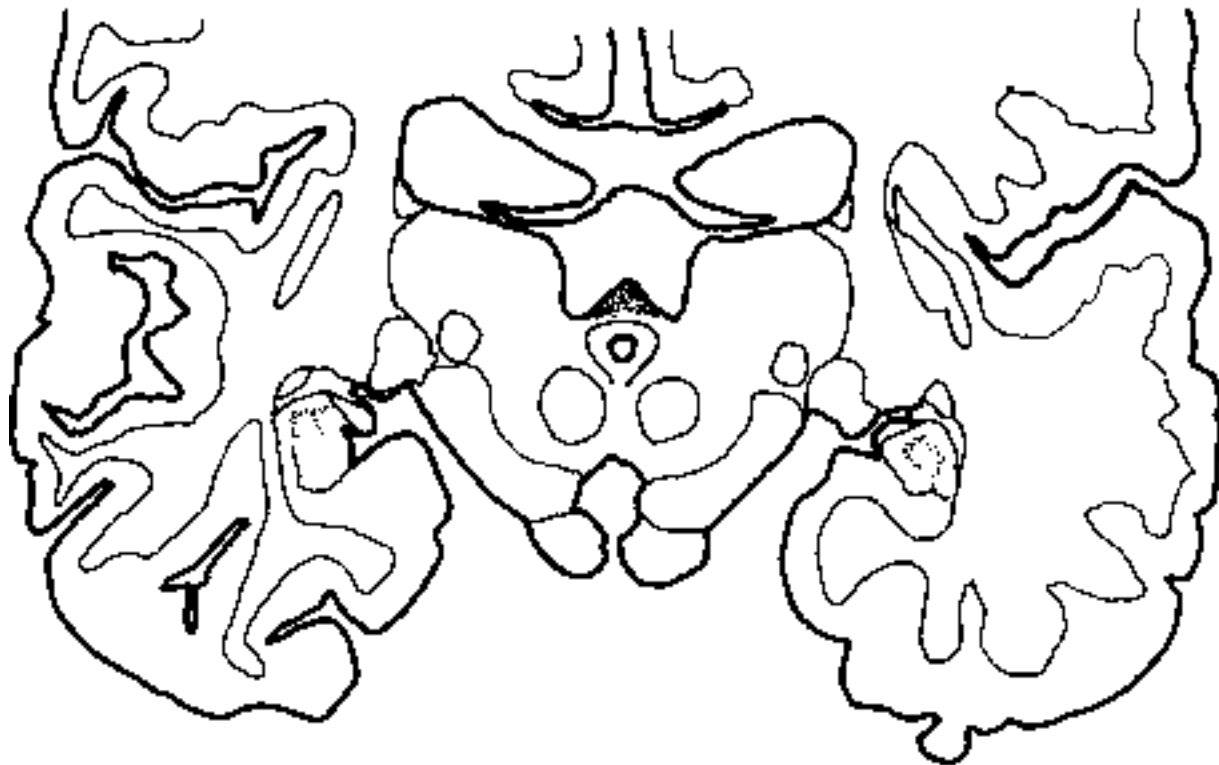
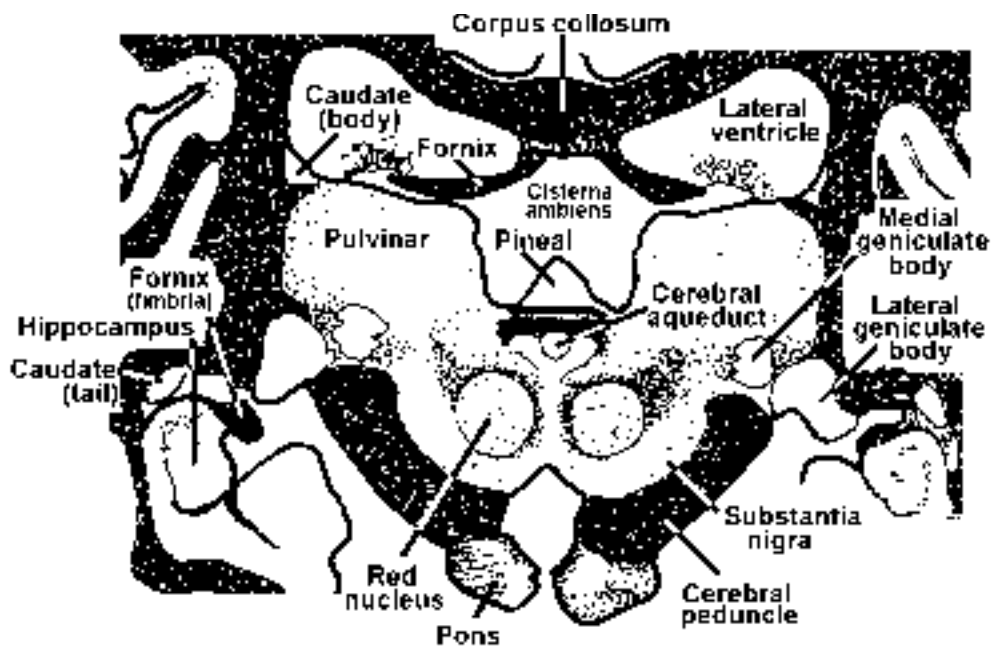


**NOTE:** The following are practice questions, the weigert stained sections will not be labeled on the exam



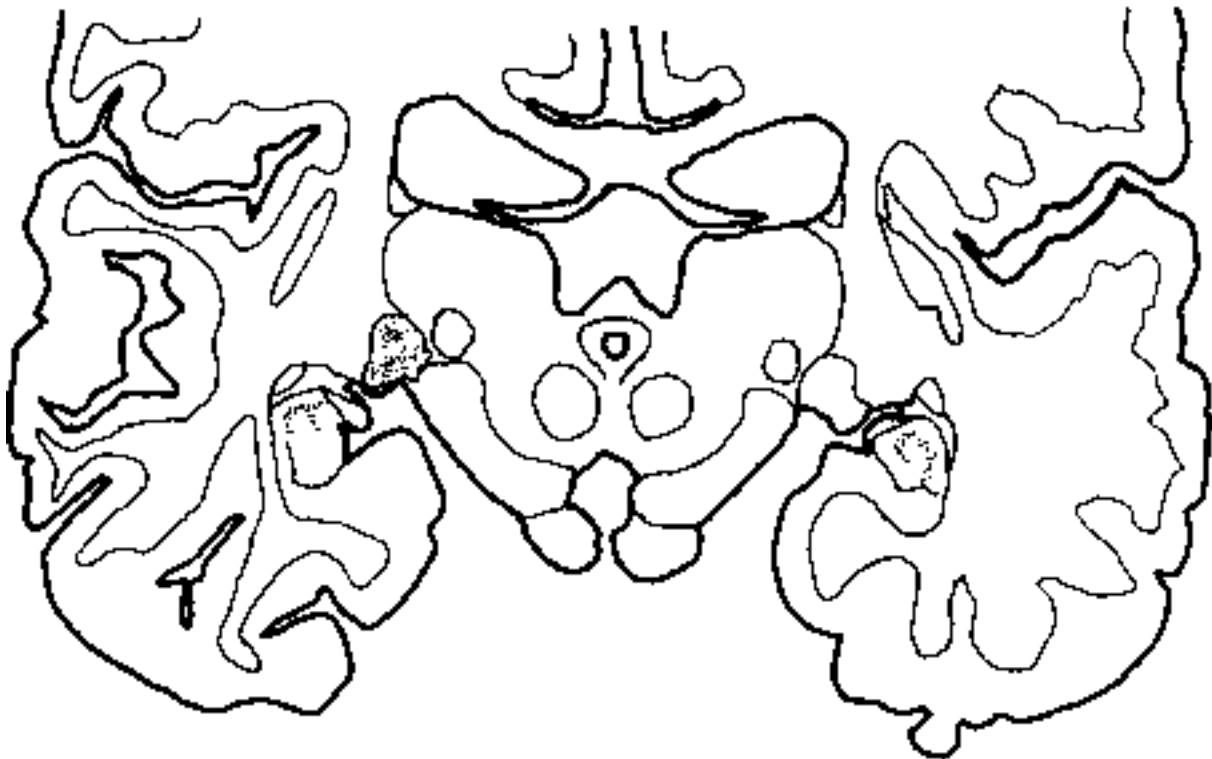
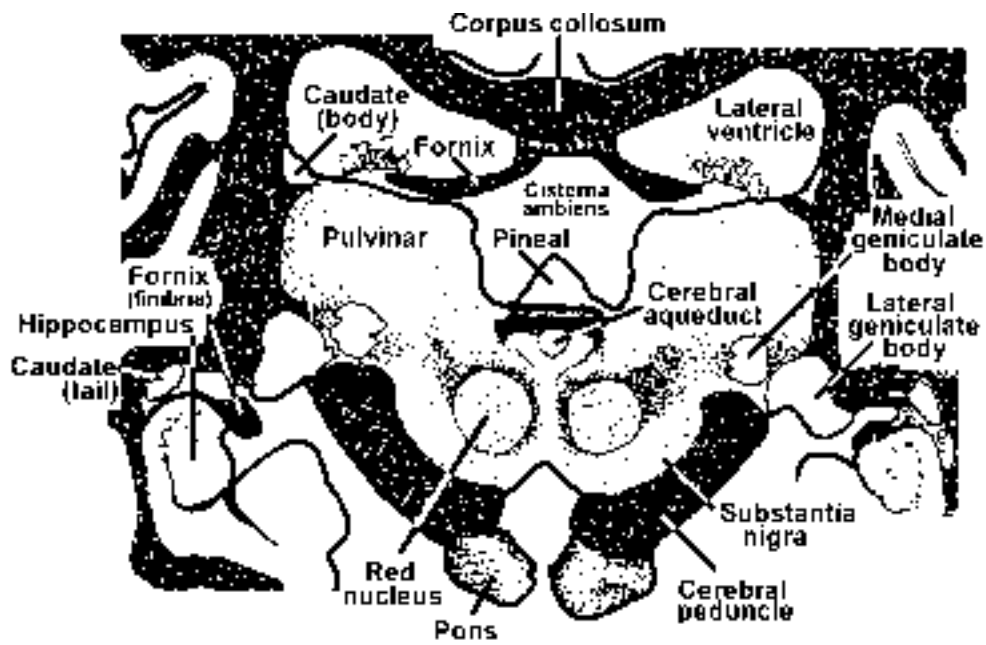
12. Which of the following statements is true regarding the shaded structure?

- A. cells project to wide areas of parietal, occipital and temporal cortex
- B. is an association nucleus
- C. receives input from the optic nerve
- D. receives input from the olfactory nerve
- E. two of the above are true



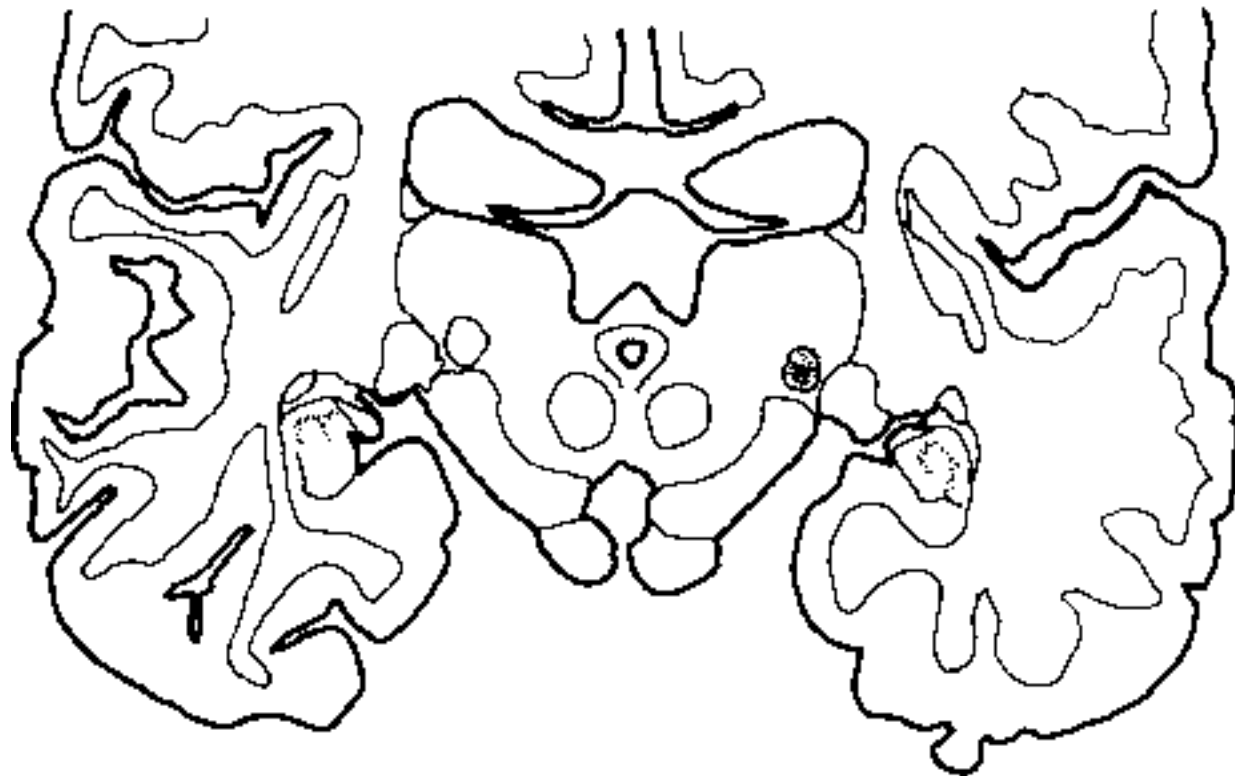
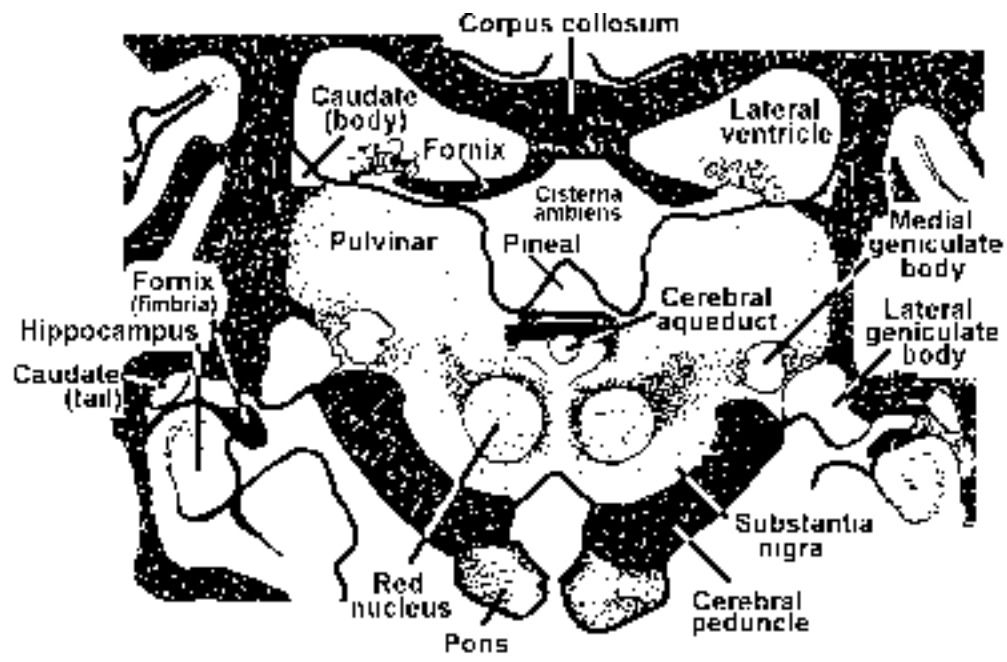
13. Which of the following statements is true regarding the shaded structure?

- A. involved in melatonin production
- B. calcifies
- C. is part of the epithalamus
- D. tumors could cause Parinaud syndrome (integrate from the brain stem module; remember the point on the superior colliculi??)
- E. all of the above are true

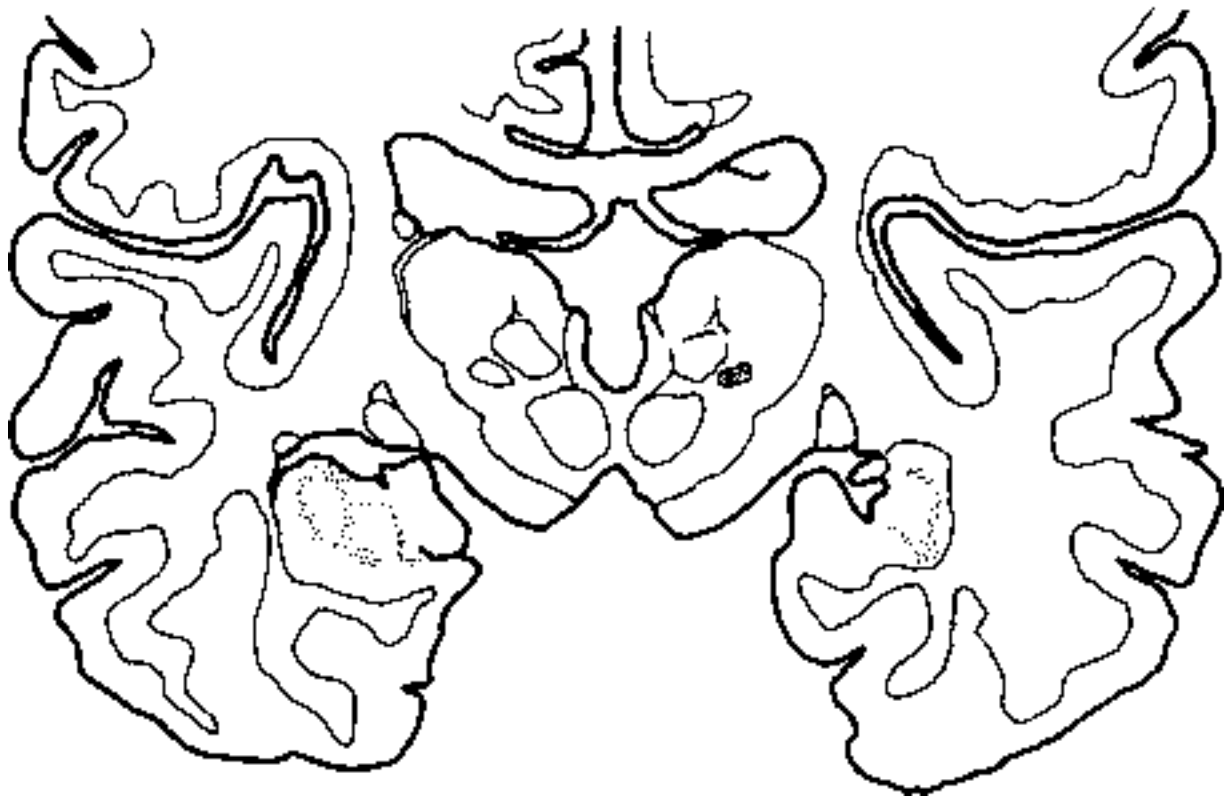
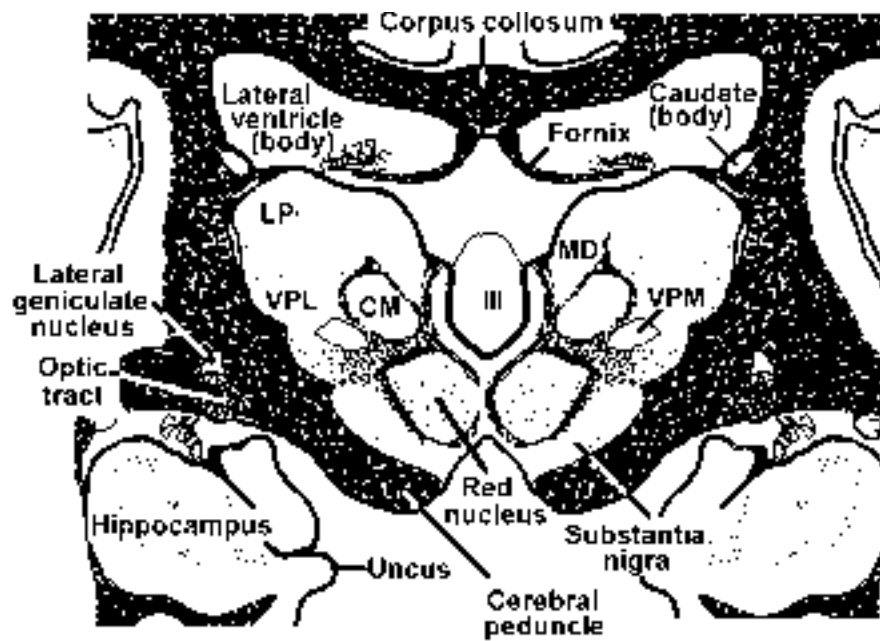


14. Which of the following statements is true regarding the shaded structure?

- A. lesion results in loss of pupillary light reflex
- B. contains cells that are driven only by one eye (monocular)
- C. cells project to area 17 via sublenticular limb of the internal capsule
- D. lesion results in bitemporal hemianopsia
- E. receives input from the temporal retina of the contralateral eye

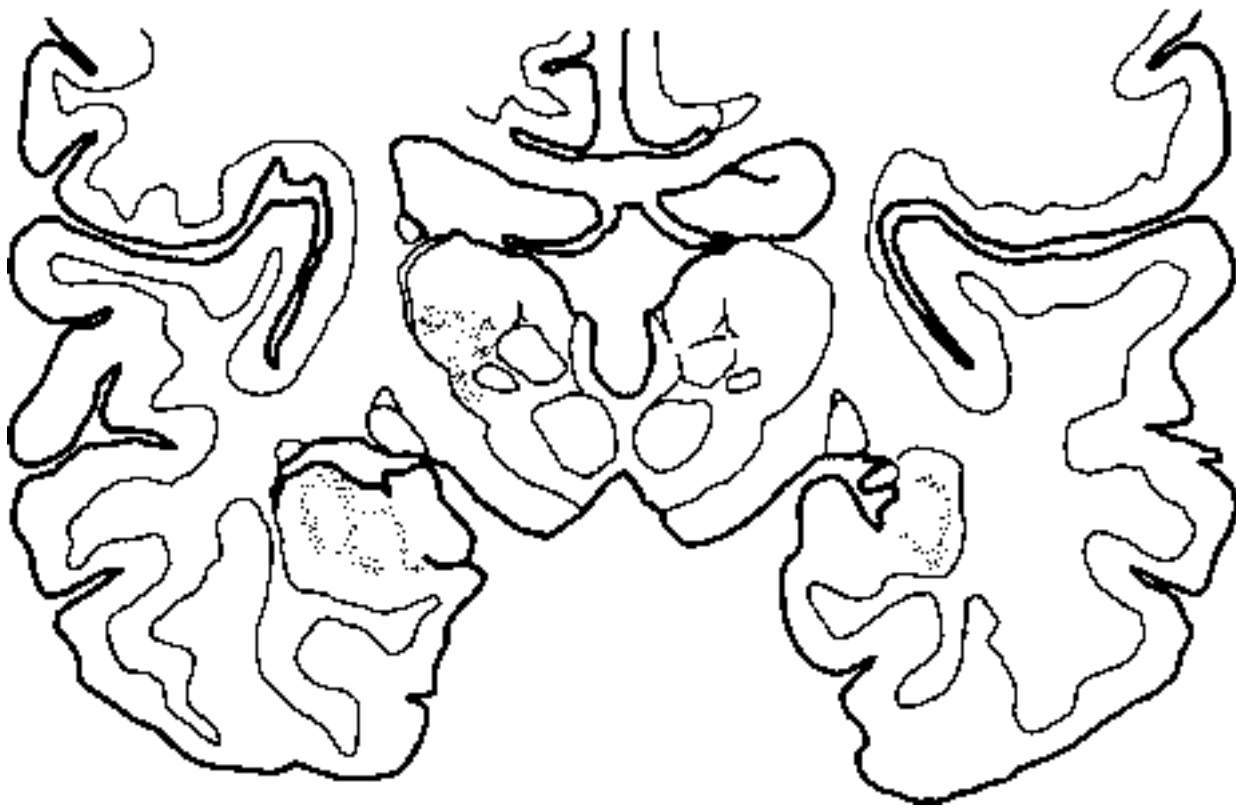
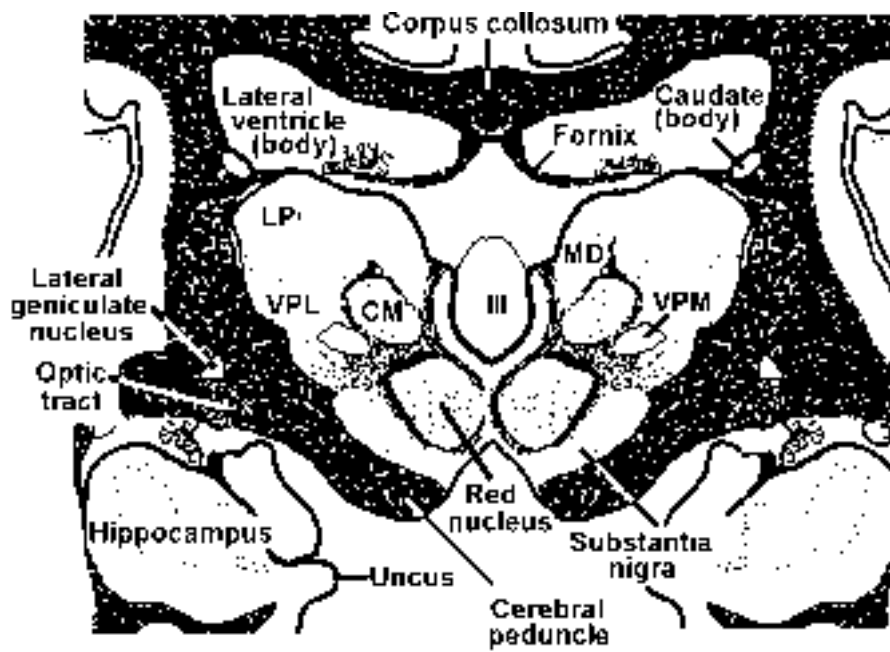


15. Which of the following statements is true regarding the shaded structure?
- A. receives input (directly or indirectly) from cells in the spiral ganglion
  - B. cells project to the cortex via the sublenticular limb of the internal capsule
  - C. cells project to areas 44 and 45
  - D. cells project to the transverse gyri of Heschl
  - E. three of the above are true



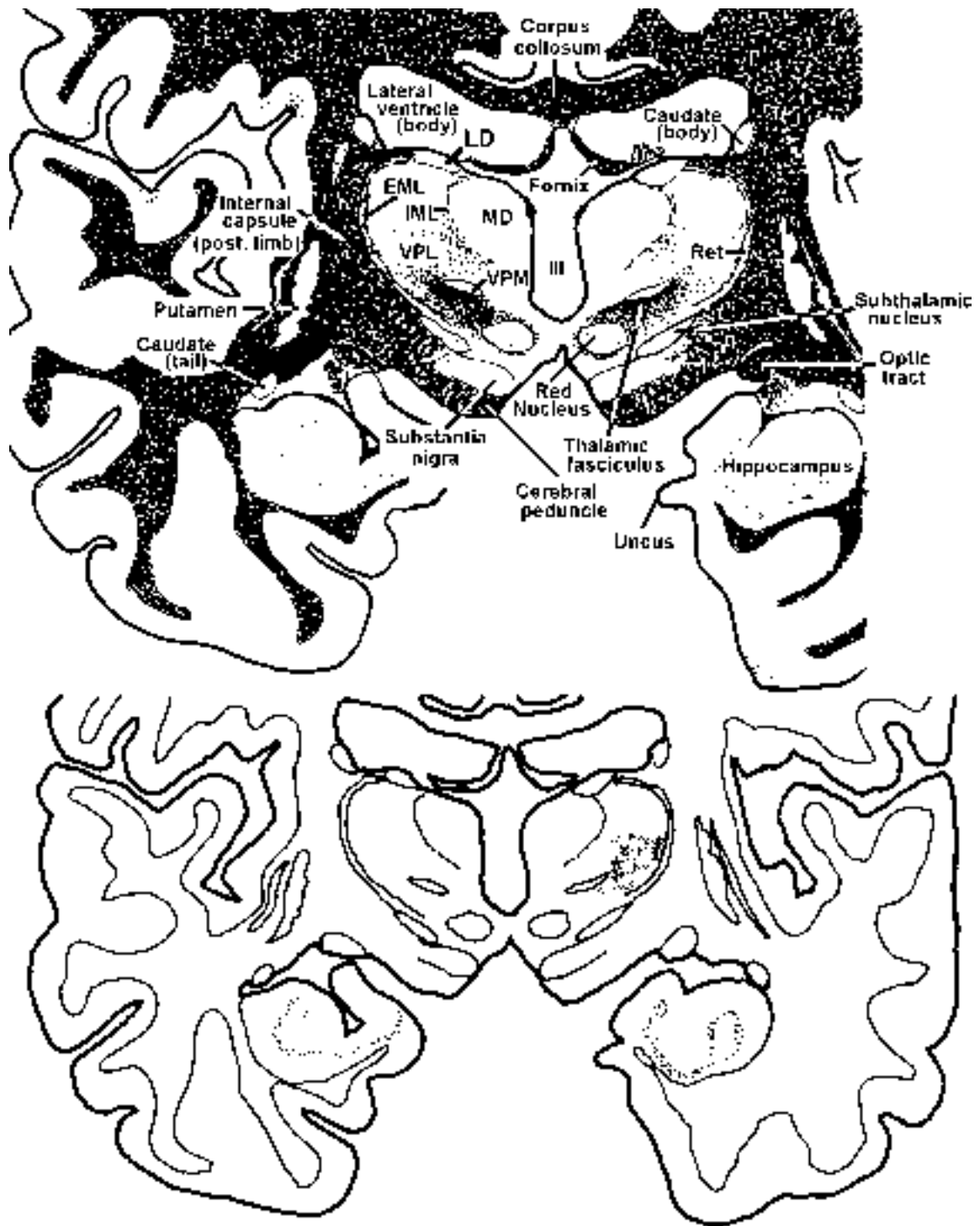
16. Which of the following statements is true regarding the shaded structure?

- A. receives input from the STT
- B. receives input from the TTT
- C. projects to cortical areas 3,1,2
- D. projects to cortex via posterior limb of the internal capsule
- E. all of the above are true



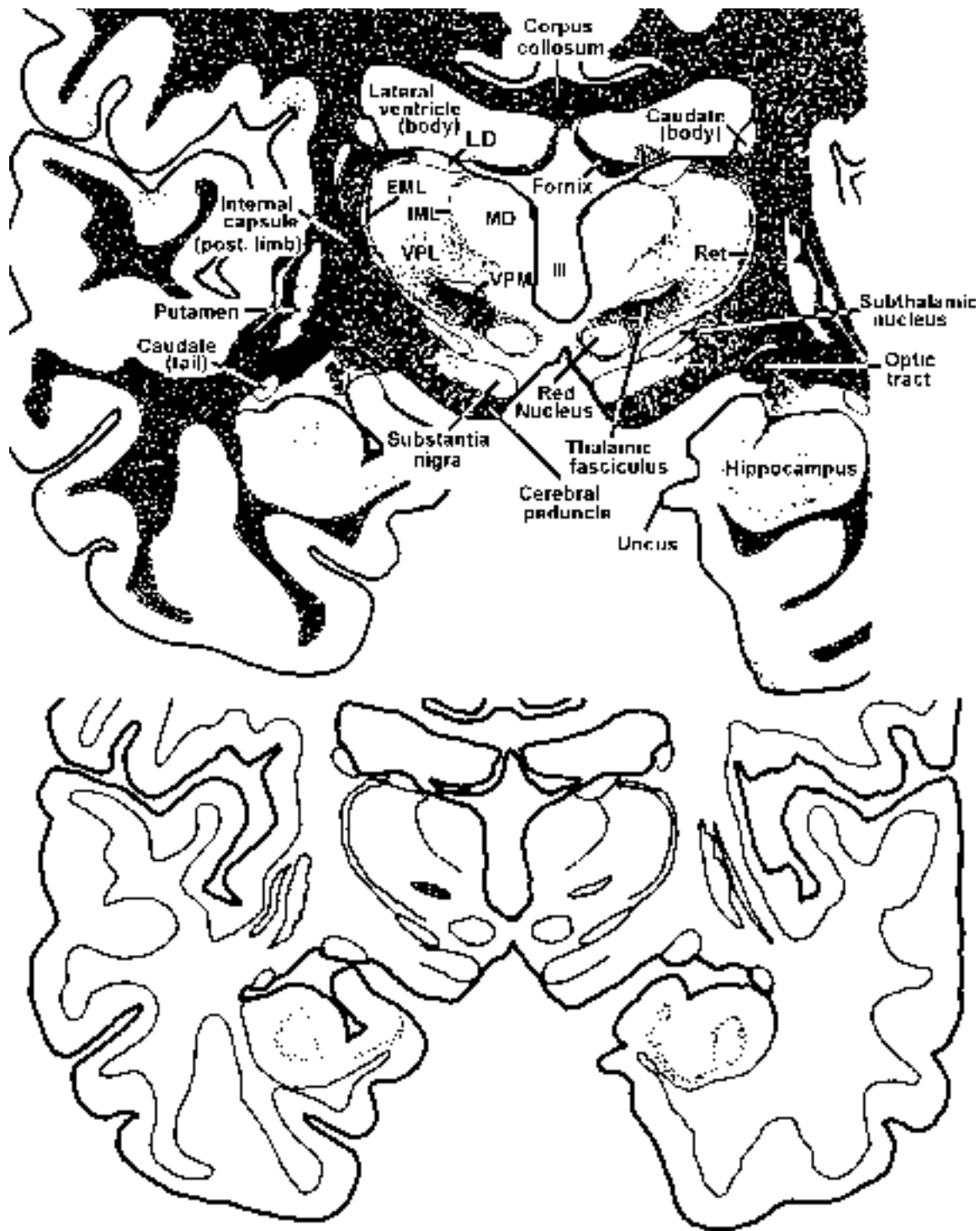
17. Which of the following statements is true regarding the shaded structure?

- A. receives input from the ALS
- B. receives input from the medial lemniscus
- C. projects to cortical areas 3,1,2
- D. projects to cortex via posterior limb of the internal capsule
- E. all of the above are true



18. Which of the following statements is true regarding the shaded structure?

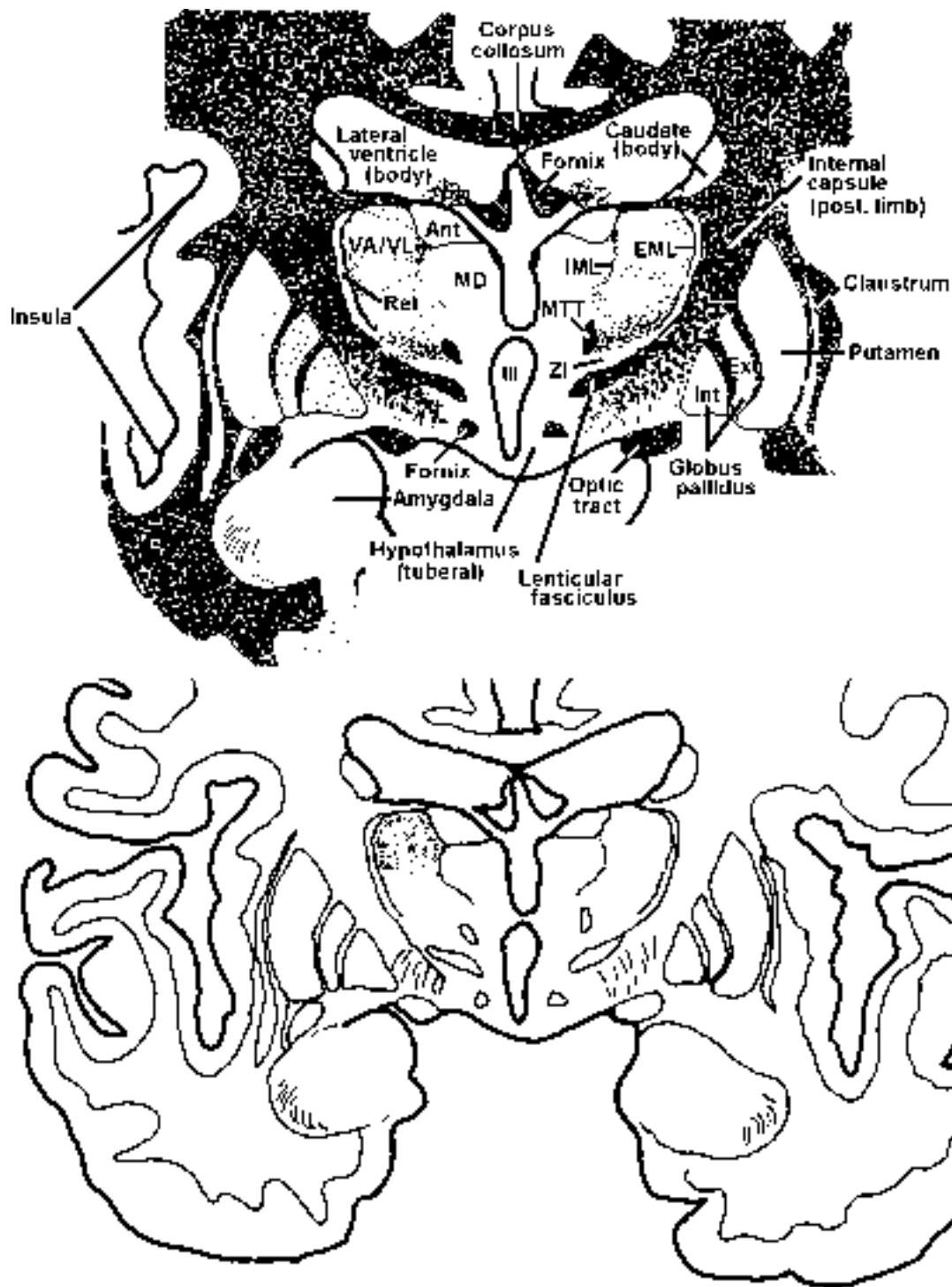
- A. receives input from the STT
- B. receives input from the TTT
- C. projects to cortical areas 3,1,2
- D. projects to cortex via posterior limb of the internal capsule
- E. two of the above are true



19. Which of the following statements is true regarding the shaded structure?

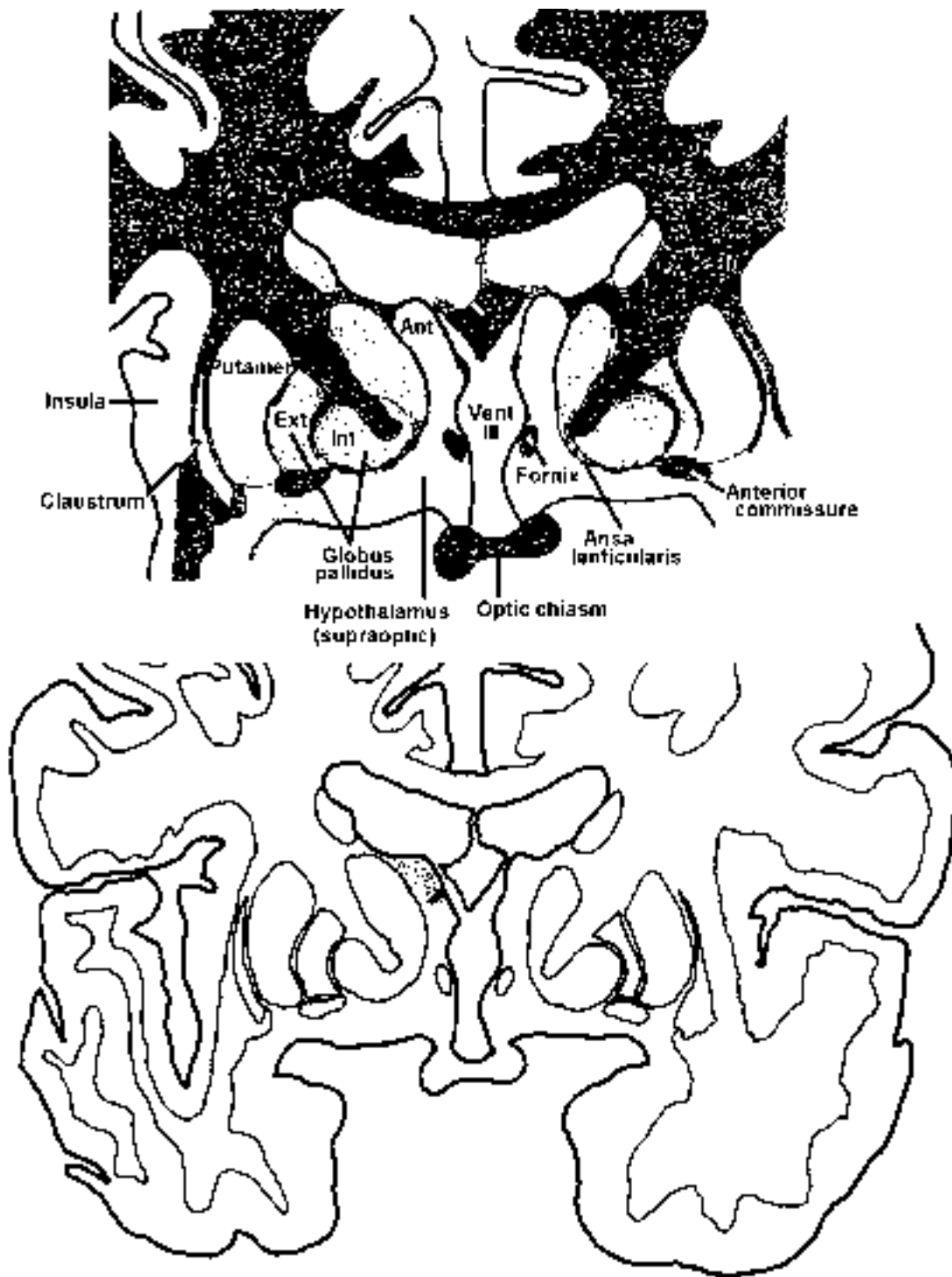
- A. receives input from the ALS
- B. receives input from the medial lemniscus
- C. projects to cortical areas 3,1,2
- D. projects to cortex via posterior limb of the internal capsule
- E. two of the above are true





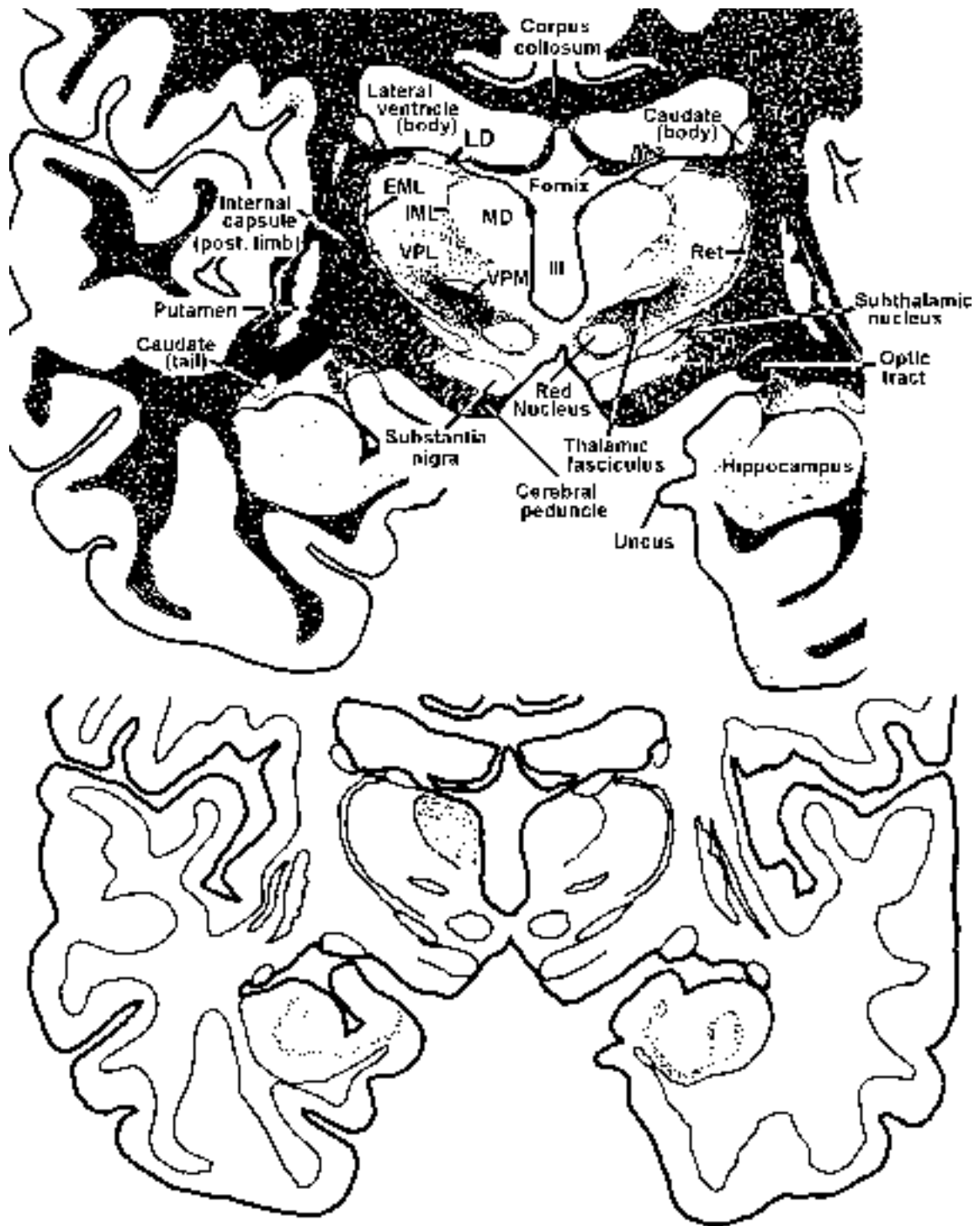
20. Which of the following statements is true regarding the shaded structure?

- A. receives input from the contralateral dentate nucleus
- B. receives input from the ipsilateral globus pallidus
- C. receives input from the ipsilateral pars reticulata of the substantia nigra
- D. projects to motor cortex
- E. all of the above are true



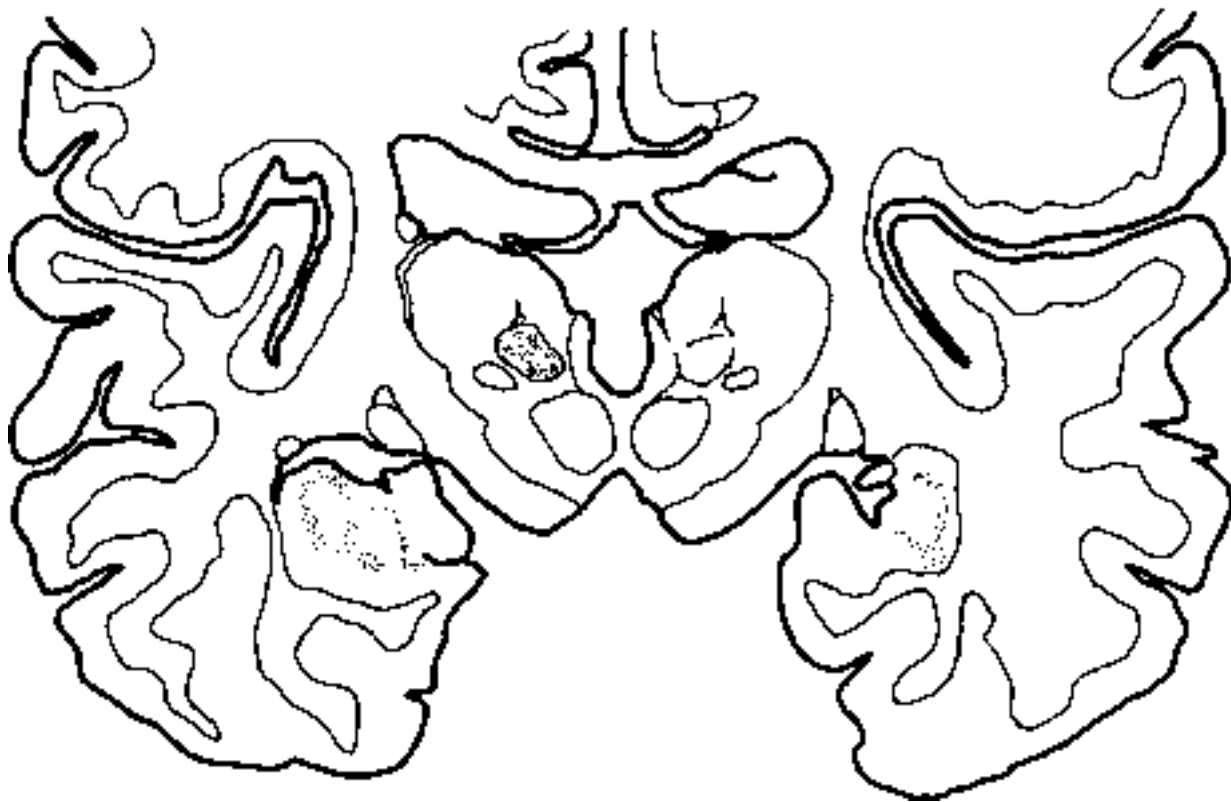
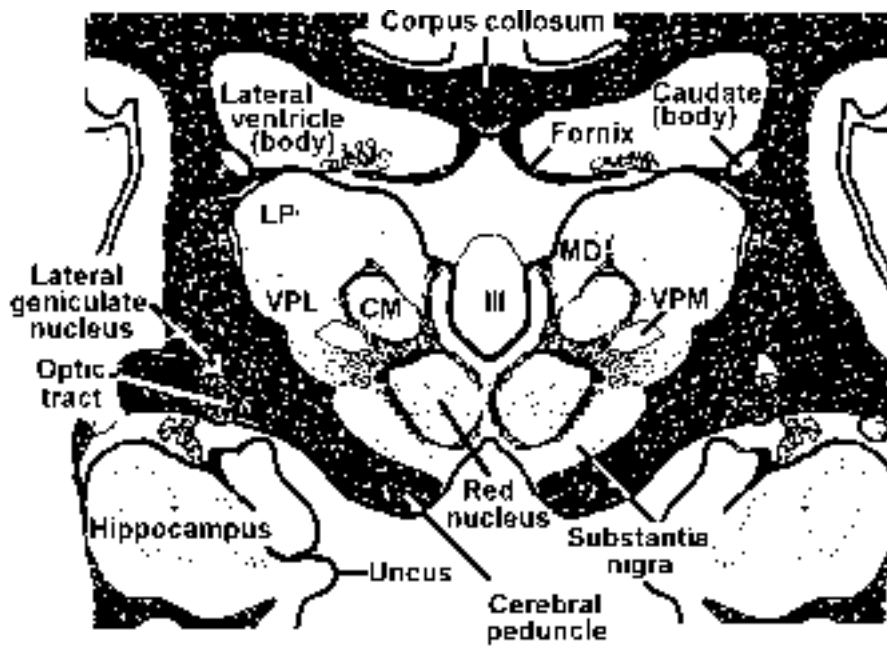
21. Which of the following statements is true regarding the shaded structure?

- A. cells receive input from the mammillary bodies
- B. cells project to cingulate cortex
- C. cells are targeted by the mammillothalamic tract
- D. cells receive input from the medial lemniscus
- E. three of the above are true



22. Which of the following statements is true regarding the shaded structure?

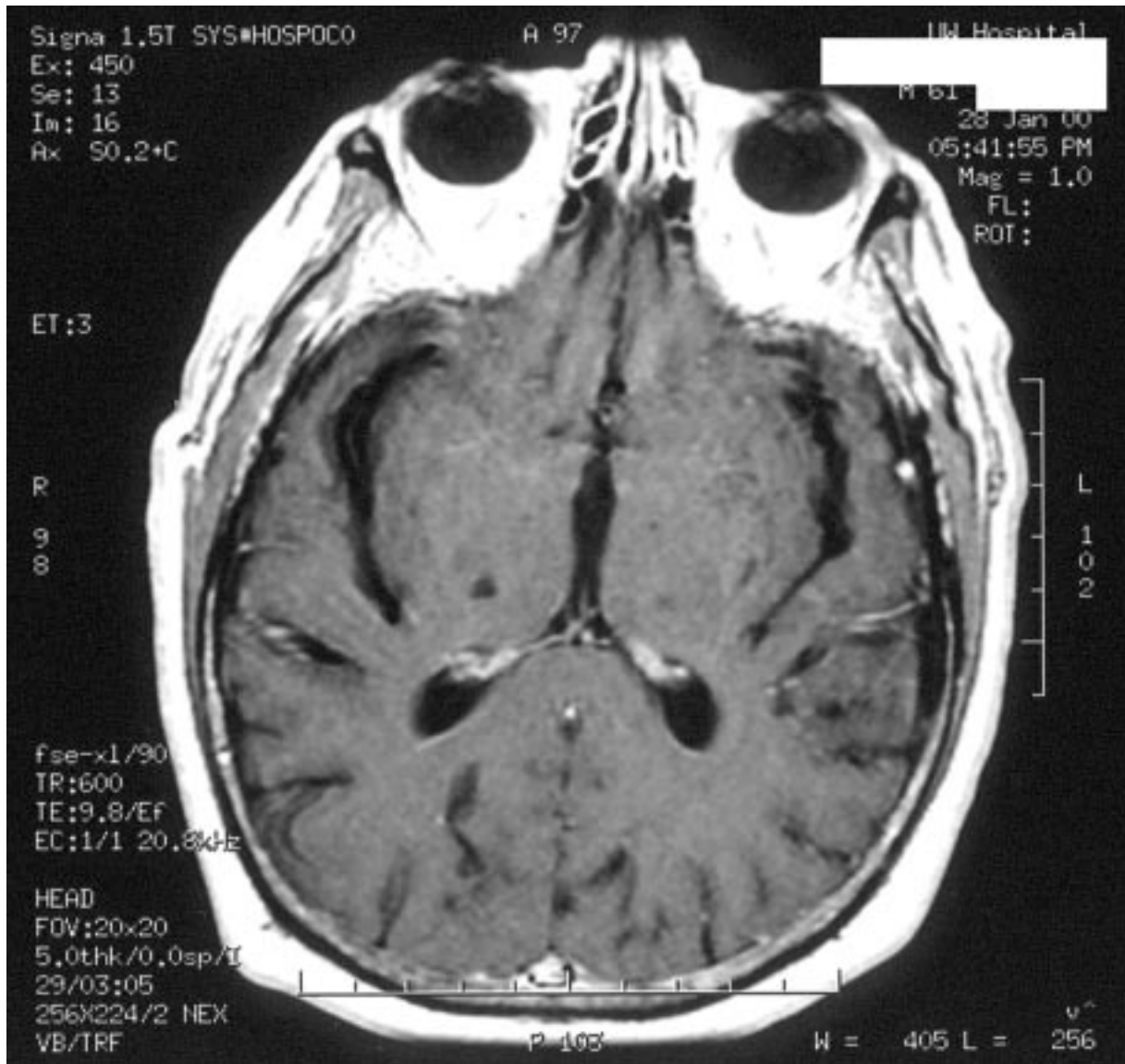
- A. cells project to extensive areas of the orbital and prefrontal cortex
- B. cells receive olfactory input
- C. cells receive pain input
- D. lesions could result in changes in emotional response to pain
- E. all of the above are true



23. Which of the following statements is true regarding the shaded structure?

- A. cells receive input from the ipsilateral globus pallidus
- B. cells receive input from the pars reticulata of the substantia nigra
- C. cells project to the striatum
- D. is the biggest of the intralaminar nuclei
- E. all of the above are true

24. A 45 y.o. woman presents to the emergency room with a headache and complains of abnormal sensations on the left side of her body. She claims that the sensory changes came on rapidly in the last few hours. Her lab reports come back normal, a spinal tap reveals normal CSF, and her mental ability seems good. You perform a neurological exam and find she has greatly reduced sensation on the entire left side of her body, including her face. The sensory loss includes all modalities. The motor exam was normal, as was her visual exam and hearing exam. An MRI was performed and the results are seen below. Select the **incorrect** statement concerning this case.



- A. The fact that all sensory modalities were involved indicates a lesion at the level of the thalamus rather than the sensory cortex.
- B. The sudden onset indicates a vascular accident.
- C. If an angiogram was performed you might expect to see a blockage in the thalamoperforant branch of the posterior cerebral artery.
- D. If this was a hemorrhagic infarct you would expect the lesion to be about the same size.
- E. If there were visual field defects you would expect the lesion to encroach on the lateral geniculate nucleus.

1. D
2. C
3. D
4. A
5. A
6. E
7. A
8. C
9. A
10. E
11. E
  
12. E (A and B)
13. E all
14. B
15. E (A, B and D)
16. E all
17. E all
18. E (C and D)
19. E (C and D)
20. E all
21. E (A, B and C)
22. E all
23. E all
24. D

## **SELF LEARNING Tuesday, March 30, 11AM-12**

Make sure you have done the practice questions on Thalamus. Watch the CD-ROM on the thalamus and perhaps get an early start on the Cerebral Cortex. Read the www reading **Brain Asymmetry** and **Dyslexia** and look over the **Cerebral Blood Supply** site.

Sorry to keep harping, but you should have read and understood the www reading regarding **Parkinson's, Tourette Syndrome, Deep Brain Stimulation, Is Our Inverted Retina Really Bad Design?, Diabetic Retinopathy, Menieres' Disease and Benign Paroxysmal Positional Vertigo.** Moreover, the old stuff should be fixed in your brains. They are: 1) muscular dystrophy, 2) myasthenia gravis, 3) Guillain-Barre, 4) S1 radiculopathy, 5) amyotrophic lateral sclerosis (ALS), 6) Brown Sequard syndrome (spinal cord hemisection), 7) facial colliculus-vestibulo-cochlear, 8) lateral medullary (Wallenberg's) syndrome, 9) acoustic neuroma, 10) Weber Syndrome, 11) syringomyelia and 12) subacute combined systems disease. Be familiar with the two cases (one Huntington's and one Parkinson's) in the practice questions following "Basal Ganglia." Finally, look over the "thalamus/Cortex power point for quiz #9.

**YOU CAN ALSO GO UP TO THE LABS AND LOOK AT THE THALAMUS AND CORTEX**